

Case Report

Autologous Chondrocyte Repair of an Articular Defect in the Humeral Head

Anthony A. Romeo, M.D., Brian J. Cole, M.D., M.B.A., Augustus D. Mazzocca, M.D., Jeff A. Fox, M.D., Kevin B. Freeman, M.D., M.S.C.E., and Edward Joy, M.D.

Abstract: Articular cartilage lesions remain a difficult problem for the patient and physician. A variety of procedures and treatments have been proposed to lessen symptoms and restore the articular surface. The knee joint has been the focus of the vast majority of these cartilage restoration procedures. Articular cartilage lesions of the humerus are significantly less common, and their management remains poorly defined. This paper presents a case report of a young athlete with a large full-thickness articular cartilage defect of the proximal humerus and subsequent treatment using autologous chondrocyte implantation. **Key Words:** Full-thickness cartilage loss—Articular cartilage—Autologous chondrocyte implantation—Shoulder—Athlete—Instability.

Articular surface lesions in any joint present a challenging problem to both patient and physician. The critical issue is that full-thickness articular cartilage defects have limited capacity to heal.¹ Many procedures and treatments have been developed to change the alignment of the joint, provide palliative relief, create reparative tissue, or completely restore the articular surface. Current literature largely relates to cartilage restoration of the knee joint.² Unfortunately, a slight incongruity caused by articular cartilage damage causes compartment overload and can lead to early degenerative joint disease.³ The appropriate management for focal chondral defects of the

humerus or glenoid is currently unknown. This report presents a single case of a young athlete with a large full-thickness articular cartilage defect of the proximal humerus and the subsequent treatment using autologous chondrocyte implantation.

CASE REPORT

The patient was an otherwise healthy 16-year-old right-hand dominant boy who, at age 14, developed insidious-onset right shoulder pain related to throwing a baseball. Initial treatment included physical therapy, activity modification including throwing, and 1 subacromial steroid injection. Failure of this nonoperative treatment led his treating physician to perform an arthroscopic subacromial decompression and thermal shrinkage of the anterior structures of the glenohumeral joint using a bipolar radiofrequency device. Two months after surgery, the patient returned to overhead activities but did not achieve complete relief from symptoms. In the subsequent months, he developed increased mechanical symptoms in his shoulder occurring with activities, as well as increased discomfort at rest and with weather changes. Symptoms were exacerbated by moving his arm in an overhead position.

From the Shoulder Section (A.A.R.), Rush Cartilage Restoration Center (B.J.C.), and Section of Sports Medicine (A.D.M., J.A.F., K.B.F.), the Department of Orthopaedic Surgery, Rush-Presbyterian-St. Luke's Medical Center, and the University of Chicago (E.J.), Chicago, Illinois, U.S.A.

Address correspondence and reprint requests to Anthony A. Romeo, M.D., Shoulder Section, Department of Orthopaedic Surgery, Rush-Presbyterian-St. Luke's Medical Center, 1725 W. Harrison St, Suite 1063, Chicago, IL 60612, U.S.A. E-mail: shoulderelbowdoc@aol.com

*© 2002 by the Arthroscopy Association of North America
0749-8063/02/1808-3481\$35.00/0
doi:10.1053/jars.2002.36144*

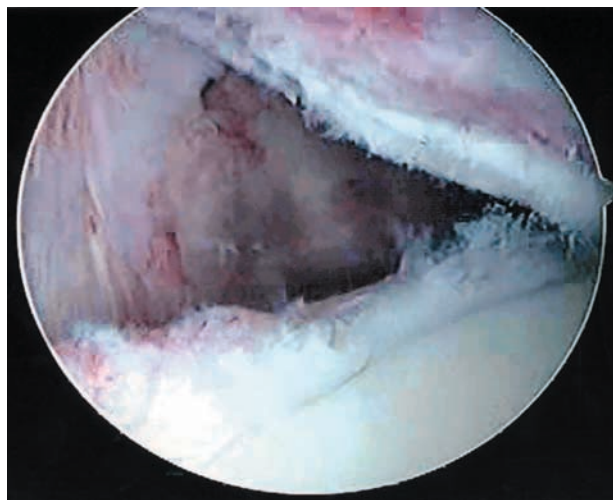


FIGURE 1. Intraoperative arthroscopic view showing capsular thermal necrosis of the anteroinferior glenohumeral joint capsule combined with complete articular cartilage loss on the anterior humeral articular load-bearing surface.

Clinical Examination

On clinical examination, the patient demonstrated full symmetrical range of motion, no impingement findings, and a lack of true apprehension in the fully abducted and externally rotated positions. The patient denied any history of anterior subluxation or dislocation before or after the surgical procedure. Posterior drawer testing resulted in painful crepitus. The posterior labral compression test was painful and reproduced some of his shoulder symptoms. The clinical examination suggested a posterosuperior labral tear, but not all of the symptoms could be attributed to this working diagnosis. A revision arthroscopic procedure was planned, with a preoperative diagnosis of a posterosuperior labral tear.

Revision Arthroscopic Stabilization

The patient was positioned in the lateral decubitus position for the arthroscopy. The examination under anesthesia demonstrated 2+ instability in the antero-inferior direction without a frank dislocation. Posterior instability was absent. During the diagnostic arthroscopy, 2 significant findings were identified. First, the anterior glenohumeral joint capsule was absent, with direct visualization of the subscapularis muscle fibers in the area of the anterior band of the inferior glenohumeral ligament as well as the anterior half of the axillary pouch of the inferior glenohumeral ligament (Fig 1). Secondly, a 3.3 × 1.5 cm full-thickness

articular cartilage defect was identified on the antero-superior aspect of the humeral articular surface bordering the central load-bearing zone of the humeral head (Fig 2). This was not evident on the arthroscopic photographs seen at the index surgical procedure. In addition, a posterosuperior labral tear was identified at the labrum directly behind the attachment site of the biceps tendon.

The surgical procedure included a general debridement of the glenohumeral joint and articular surface. After the initial step, an arthroscopic stabilization of the posterosuperior labral tear was performed with two bioabsorbable suture anchors loaded with braided nonabsorbable sutures. Following the labral stabilization, a suture plication of any remaining inferior and anterior glenohumeral joint capsule was completed with nonabsorbable braided sutures. The suture plication included the normal labrum, a small amount of normal-appearing capsule adjacent to the labrum, and part of the thermally treated tissue that remained attached to the glenohumeral joint capsule. When this tissue was insufficient to hold the suture, the suture was passed through the fibrous layer of the subscapularis and incorporated into the suture plication stitch. The goal of the plication was to create a tissue “tuck” of approximately 1.5 cm, creating a bumper on the edge of the glenoid. This plication would hopefully create a scaffold to re-establish the glenohumeral joint capsule. The rotator interval was then closed using a prolonged absorbable suture passed through the superior glenohumeral ligament, the superior edge of the subscapularis, and middle glenohumeral ligament. At

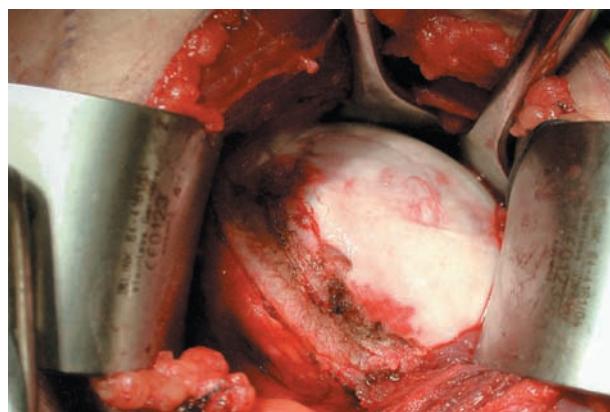


FIGURE 2. Intraoperative photograph showing a 3.3 × 1.5 cm articular cartilage lesion covered by a thin layer of fibrous tissue. This lesion involves the anterior aspect of the humeral articular surface. The subscapularis and capsule were incised as a single layer.

the completion of the surgical procedure, the excessive anteroinferior translation had been eliminated.

Because recurrent instability was a greater concern than postoperative stiffness, the patient was immobilized for the first month after surgery. After 1 month, a rehabilitation program with a conservative range of motion was initiated, consisting of 90° of forward elevation and 20° of external rotation in adduction and abduction. At 6 weeks, the rehabilitation program emphasized range of motion and strengthening of the rotator cuff and scapular stabilizers. Over the next 4 months the program advanced to include weight training. Examination at 6 months postoperatively demonstrated only 10° of external rotation in abduction. As he advanced through a throwing program, the patient reported no subjective complaints of instability. Unfortunately, however, the patient complained of progressively worsening deep shoulder discomfort with extended periods of throwing, changes in the weather, and with additional strengthening exercises. These complaints were believed to be consistent with symptoms associated with the articular cartilage damage identified at the time of revision stabilization. On clinical examination, the patient continued to have mild crepitation with the posterior drawer test, but this was substantially reduced from the preoperative examination. He had no evidence of anterior instability, including a negative relocation test and a negative apprehension test. Furthermore, the O'Brien test for superior labral pathology was unremarkable.

Based on the clinical findings and the patient's subjective complaints, a decision was made to proceed with autologous chondrocyte implantation after performing magnetic resonance imaging (MRI). The MRI failed to demonstrate any abnormality of the subchondral bone adjacent to the full-thickness articular cartilage defect. In particular, there were no findings consistent with avascular necrosis. The decision to perform autologous chondrocyte implantation was partially based on the success of this procedure when used for similar-sized full-thickness articular cartilage defects of the knee.⁴ It was theorized that, given the relatively low loads across the glenohumeral joint compared with the knee joint, autologous chondrocyte implantation of the humerus would be likely to provide significant symptomatic relief.

Autologous Chondrocyte Implantation

A knee arthroscopy was performed to harvest 200 g of autologous cartilage. The cartilage was taken from the intercondylar notch in the same region in which a

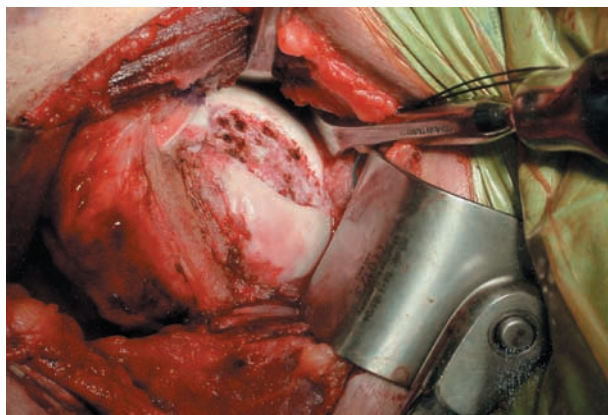


FIGURE 3. Preparation of the articular bed includes establishing a well-shouldered lesion and achieving hemostasis with the use of epinephrine-soaked sponges. The tidemark has not been violated. The transition zone has been removed, and there are 90° angles at the cartilage-bone interface in preparation for the autologous chondrocyte implantation.

notchplasty is typically performed during anterior cruciate ligament reconstruction. This tissue was sent to Genzyme Biosurgery (Cambridge, MA) for culturing.

The autologous chondrocyte procedure was performed within 1 month. Examination under anesthesia demonstrated no residual anteroinferior instability. The defect was exposed through a typical anterior deltopectoral approach with lateral detachment of the capsule and subscapularis from the lesser tuberosity. Examination of the capsule demonstrated a thickened and relatively normal-appearing structure. The capsular plication and capsulolabral bumper established along the anteroinferior glenoid remained intact.

The defect was easily visualized. The fibrocartilagenous tissue was sharply debrided using a ringed curette, leaving the tidemark intact at the base. The articular cartilage defect measured 3.3×1.5 cm. The articular edges were debrided to produce an edge perpendicular to the subchondral bone. It was noted that the humeral articular surface was significantly thinner than the femoral condyle of the knee and had a tendency to bleed more readily during debridement. Epinephrine-soaked neuropatties were used to establish hemostasis at the base of the defect (Fig. 3.) A slightly oversized periosteal patch was harvested from the medial tibia distal to the pes anserine tendon complex. The periosteal patch was sewn to the remaining articular cartilage using 6-0 vicryl sutures, leaving a small opening for injection of the chondrocyte suspension (Fig 4). Fibrin glue was applied to the periphery of the periosteal patch to provide a circum-

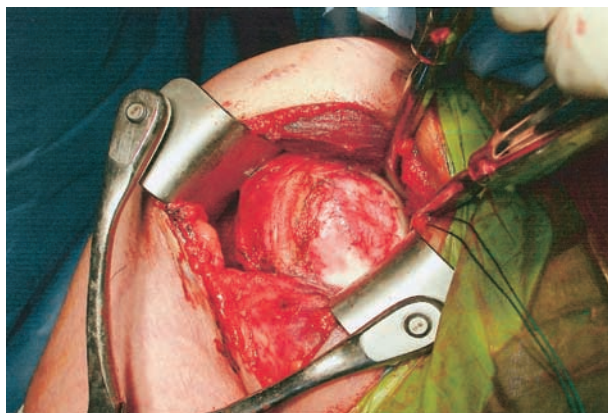


FIGURE 4. A periosteal patch harvested from the patient's knee has been secured to the articular cartilage defect with a 6-0 monofilament suture and the application of fibrin glue at the junction between the periosteal patch and the articular cartilage.

ferential watertight seal. The chondrocytes were re-suspended and injected through the small opening at the superior aspect of the patch, which was closed with additional sutures and sealed with fibrin glue. The humerus was reduced into the glenoid fossa, and the subscapularis and glenohumeral capsule were closed as a single layer to the remaining soft tissues on the lesser tuberosity using No. 5 non-absorbable braided suture. The deltopectoral fascia was then closed with absorbable suture, and the wound was closed in a routine fashion. The patient's arm was placed in a sling and swathe-type brace.

During the early postoperative period, the patient was placed on 6 to 8 hours of continuous passive motion each day. After 4 weeks, he was allowed active-assisted and active motion to 90° of elevation and 20° of external rotation. At 6 weeks he advanced to 140° of elevation and 40° of external and internal rotation. At 12 weeks, he was allowed range of motion and strengthening as tolerated. At 12 months, the patient demonstrated full range of painless motion with no further complaints of rest pain or pain related to weather changes.

DISCUSSION

The management of focal articular cartilage defects of the humerus or glenoid remains challenging. In this particular case, the etiology of this defect remains obscure. Theoretically, given the proximity of the capsule treated, the initial use of a bipolar radiofrequency device to treat the capsule in this patient may provide concern for subsequent cartilage damage. Be-

cause the articular surface of the humeral head is relatively thin and the potential exists for full-thickness cartilage loss, the use of radiofrequency devices on the articular surface of the humeral head is considered contraindicated by these authors.⁵⁻⁸

At this time, no scientific studies provide conclusive evidence that autologous chondrocyte implantation will be as successful for the treatment of humeral articular cartilage defects as it has been for articular cartilage defects of the knee. However, other cartilage restoration procedures, such as microfracture or osteochondral grafting, are also not supported for the treatment of focal cartilage defects of the shoulder. Theoretically these procedures appear less appropriate for the lesion identified in this young patient.⁹

In our opinion, this treatment is a reasonable option for future patients with similar articular cartilage defects involving the humeral articulating surface.¹⁰⁻¹² If this procedure had failed, our next choice for cartilage restoration would be a fresh osteochondral allograft harvested from a size-matched humerus. In young patients, osteochondral allografts are a less appealing initial treatment because of the obligate destruction of the subchondral bone and the lack of additional alternatives should that treatment modality fail.

Current concepts regarding cartilage restoration suggest that autologous chondrocyte implantation may be appropriate for the shoulder because of the relatively low loads across the glenohumeral joint. However, because high shear stress occurs during glenohumeral rotation, especially during end ranges of motion, returning to activities such as throwing a baseball are likely to jeopardize the integrity of the autologous chondrocyte implantation. Therefore, we do not recommend patients return to such activities until further follow-up has provided evidence that the sites of autologous chondrocyte transfer are well incorporated into the patient's cartilage. Although these defects are less common, the management of full-thickness symptomatic chondral defects of the humeral head may provide another indication for autologous chondrocyte implantation.

REFERENCES

1. Mankin HJ. Current concepts review: The response of articular cartilage to mechanical injury. *J Bone Joint Surg Am* 1982;64:460-466.
2. Curl WW, Krome J, et al. Cartilage injuries: A review of 31,516 knee arthroscopies. *Arthroscopy* 1997;13:456-460.
3. Messner K, Maletius W. The long-term prognosis for severe damage to the weight-bearing cartilage of the knee. *Acta Orthop Scand* 1996;67:165-168.

4. D'Amato M, Cole BJ. Autologous chondrocyte implantation. *Orthop Techn* 2001;11:115-131.
5. Hogan CJ, Diduch DR. Progressive articular cartilage loss following radiofrequency treatment of a partial-thickness lesion. *Arthroscopy* 2001;17:E24.
6. Edwards RB, Lu Y, Nho S, et al. Thermal chondroplasty of chondromalacic human cartilage: An *ex vivo* comparison of bipolar and monopolar radiofrequency devices. *Am J Sports Med* 2002;30:90-97.
7. Lu Y, Edwards RB, Cole BJ, Markel MD. Thermal chondroplasty with radiofrequency energy: An *in vitro* comparison of bipolar and monopolar radiofrequency devices. *Am J Sports Med* 2001;29:42-49.
8. Lu Y, Edwards RB, Kalscheur VL, et al. Effect of bipolar radiofrequency on human articular cartilage: Comparison of fluorescent vital cell staining and light microscopy. *Arthroscopy* 2001;17:117-123.
9. Gerber C, Lambert SM. Allograft reconstruction of segmental defects of the humeral head for the treatment of chronic locked posterios dislocation of the shoulder. *J Bone Joint Surg Am*, 1996;78:376-382.
10. Brittberg M, Nillsson A, et al. Treatment of deep cartilage defects in the knee with autologous chondrocyte transplantation. *N Engl J Med* 1994;331:889-895.
11. Peterson L, Brittberg M, et al. Autologous chondrocyte transplantation: Biomechanics and long-term durability. *Am J Sports Med* 2002;30:2-12.
12. Peterson L, Minas T, et al. Two to nine year outcome after autologous chondrocyte transplantation of the knee. *Clin Orthop Rel Res* 2000;374:212-234.