

American Journal of Sports Medicine

<http://ajs.sagepub.com>

Clinical Outcomes After Subpectoral Biceps Tenodesis With an Interference Screw
Augustus D. Mazzocca, Mark P. Cote, Cristina L. Arciero, Anthony A. Romeo and Robert A. Arciero
Am. J. Sports Med. 2008; 36; 1922 originally published online Aug 12, 2008;
DOI: 10.1177/0363546508318192

The online version of this article can be found at:
<http://ajs.sagepub.com/cgi/content/abstract/36/10/1922>

Published by:



<http://www.sagepublications.com>

On behalf of:



[American Orthopaedic Society for Sports Medicine](http://www.aossm.org)

Additional services and information for *American Journal of Sports Medicine* can be found at:

Email Alerts: <http://ajs.sagepub.com/cgi/alerts>

Subscriptions: <http://ajs.sagepub.com/subscriptions>

Reprints: <http://www.sagepub.com/journalsReprints.nav>

Permissions: <http://www.sagepub.com/journalsPermissions.nav>

Clinical Outcomes After Subpectoral Biceps Tenodesis With an Interference Screw

Augustus D. Mazzocca,^{*†} MS, MD, Mark P. Cote,[†] PT, Cristina L. Arciero,[†] Anthony A. Romeo,[‡] MD, and Robert A. Arciero,[†] MD

From the [†]Department of Orthopaedic Surgery, New England Musculoskeletal Institute, University of Connecticut Health Center, Farmington, Connecticut, and the [‡]Department of Orthopaedic Surgery, Rush-Presbyterian-St. Luke's Medical Center, Chicago, Illinois

Background: Subpectoral biceps tenodesis with an interference screw has been shown to be an effective procedure from both an anatomic and biomechanical perspective. There have been no clinical outcome data on this procedure to date.

Hypothesis: Subpectoral biceps tenodesis is an effective procedure in eliminating biceps tendinosis symptoms.

Study Design: Case series; Level of evidence, 4.

Methods: Patients who underwent subpectoral biceps tenodesis with a minimum follow-up of 1 year were evaluated using a battery of clinical outcome measures, biceps apex difference, and pain scores. A diagnosis of biceps tendinosis was made using a specific diagnostic protocol coupled with observation of biceps tendon fraying and increased erythema on dry arthroscopy.

Results: Between November 2002 and August 2005, 50 patients underwent subpectoral biceps tenodesis. Complete follow-up examinations were performed in 41 of 50 (82%). There were 16 women and 25 men (mean age, 50 years). Follow-up averaged 29 months (range, 12-49 months). The mean scores were 86, Rowe; 81, American Shoulder and Elbow Surgeons (ASES); 9, Simple Shoulder Test (SST); 87, Constant Murley; and 84, Single Assessment Numeric Evaluation (SANE). There was 1 failure as demonstrated by pull-out of the tendon from the bone tunnel resulting in a "Popeye" deformity on physical examination. The mean value for biceps apex distance was 0.15 cm, with 35 of 41 patients demonstrating no difference on physical examination. Twenty-three of 41 patients had complete preoperative and postoperative examinations. All clinical outcome measures demonstrated a statistically significant improvement at follow-up when compared with the preoperative scores. Thirty-one patients had identified lesions of the rotator cuff at time of arthroscopy. The mean ASES score in patients without rotator cuff lesion (89.2 ± 10.3) was significantly greater than the mean ASES for those with rotator cuff lesion (78.0 ± 21.0) ($P = .0324$). The mean SST score in patients without rotator cuff lesion (10.6 ± 1.5) was significantly greater than the mean ASES score for those with rotator cuff lesion (8.8 ± 2.7) ($P = .0132$).

Conclusion: Subpectoral biceps tenodesis with an interference screw is a viable treatment option for patients with symptomatic biceps tendinosis. Anterior shoulder pain and biceps symptoms were resolved with this technique. Patients with coexistent rotator cuff lesion had less favorable outcomes.

Keywords: shoulder; biceps tenodesis; biceps tendinosis; outcomes

Tenodesis of the long head of the biceps is a procedure for relieving pain caused by intractable biceps tendinosis or

instability. A multitude of procedures to accomplish this task have been reported in the literature, including the keyhole, bone tunnel, suture anchor, arthroscopic, and interference screw techniques.^{3,6,8,10,11,13,16,19} The interference screw technique improved fixation strength and surgical efficiency but still required a guide wire to exit the posterior aspect of the shoulder.³ A driver capable of reducing a tendon into the bone tunnel was developed for arthroscopic procedures but due to some early failures, arthroscopic techniques were abandoned by our group. Residual pain in the bicipital groove after arthroscopic or proximal groove tenodesis may be secondary to persistent tenosynovitis or stenosis. The subpectoral approach

*Address correspondence to Augustus D. Mazzocca, MS, MD, Department of Orthopaedic Surgery, New England Musculoskeletal Institute, University of Connecticut Health Center, 263 Farmington Avenue, Farmington, CT 06034-4037 (e-mail: admazzocca@yahoo.com).

One or more of the authors has declared a potential conflict of interest: Drs Mazzocca, Romeo, and Arciero have received grant/research support from Arthrex Inc.

removes the tendon completely from the intertubercular groove and is an anatomically reproducible approach. The interference screw adds strength and ease to the procedure. This combination of anatomic placement and reliable strength is the perceived advantage of this technique.

The surgical technique and the biomechanics of the subpectoral tenodesis screw fixation procedure have been previously reported.^{14,15} To our knowledge, there are little clinical data with the use of this technique. The purpose of this study was to evaluate the clinical outcomes in patients who underwent a subpectoral biceps tenodesis using an interference screw. Our hypothesis was that there would be improvement in shoulder pain or overall patient clinical satisfaction in biceps pain using the subpectoral biceps tenodesis with an interference screw.

MATERIALS AND METHODS

This is a prospective case series of a single surgeon's (A.D.M.) practice of subpectoral biceps tenodesis. All patients diagnosed with biceps tendinosis from August 2002 to August 2005 were identified and prospectively followed. Patients were included in this study if they met the diagnostic criteria for biceps tendinosis, had failed conservative management, and underwent a subpectoral biceps tenodesis. Patients who were surgically managed with a biceps tenotomy or patients who eliminated their symptoms through conservative management were excluded. This left a study group of 50 patients (Figure 1).

Diagnostic Criteria

A diagnosis of biceps tendinosis was made using specific diagnostic criteria including consistent history, physical examination findings, and special testing. All patients complained of pain radiating down the anterior aspect of the humerus as well as pain on palpation to the intertubercular groove and subpectoral triangle. The intertubercular groove was found by palpating the anterior shoulder approximately 7 cm below the acromion with the arm internally rotated 10°. In proximal biceps tendinosis, tenderness over the intertubercular groove should move laterally with external rotation as the groove rotates.⁹ Pain in the subpectoral triangle was isolated using the subpectoral biceps tendinosis test. This is a 2-part test in which the examiner attempts to reproduce the patient's symptoms through palpation of the biceps tendon and then eliminate them through an intra-articular injection. The examiner resists the patient contracting in adduction and internal rotation. This technique allows the examiner to identify the pectoralis tendon. The examiner's index finger is then inserted into the axilla, palpating the biceps under the pectoralis muscle tendon unit (Figure 2A). This position is extra-articular but intrasynovial. Pain elicited is considered a positive test and is indicative of biceps tendinosis (Figure 2B). Because this maneuver may produce discomfort in a normal shoulder, the test is performed on the unaffected side to ensure a true positive finding. The second portion of this test is performed if a positive test was elicited by the first portion. Five milliliters of 1%

lidocaine, 5 mL of 0.5% bupivacaine, and 1 mL (40 mg) of methylprednisolone are injected into the glenohumeral joint from the anterior approach. Injecting into the glenohumeral joint takes advantage of the intrasynovial anatomy of the biceps and is thought by us to be more reliable than injecting the biceps itself. This is analogous to fluid seen in the biceps sheath on MRI arthrogram. The patient is allowed to recover and then the subpectoral test is repeated 3 to 5 minutes after the injection. If the pain is significantly removed from the subpectoral area, this implicates the biceps as a possible source of pain (Figure 2C).

Operative Treatment

The decision to surgically treat biceps tendinosis was made on a clinical presentation of bicipital groove pain, provocative tests, and response to injection that implicated the biceps tendon as a significant source of pain and disability. All patients had failed conservative management, including optimization of scapular stabilizers, stretching of the conjoined tendon, and activity modification. Significant proximal biceps pathologic changes were confirmed in all cases during arthroscopic examination. The subpectoral biceps tenodesis technique has been previously reported. It involves a 2- to 3-cm incision in the axilla, identification of the inferior pectoralis muscle tendon junction, and retraction of the tendon superiorly and laterally. The proximal biceps tendon, which has been tenotomized arthroscopically, is found directly posterior to the pectoralis muscle/tendon unit. A No. 2 nonabsorbable suture is locked onto the tendon after all except 2 cm of tendon proximal to the muscle has been removed. An 8-mm bone tunnel is carefully created only in the anterior cortex of the proximal humerus, proximal to the pectoralis muscle tendon unit. An 8 × 12 bioabsorbable tenodesis interference screw (Arthrex Inc, Naples, Florida) with a "tenodesis driver" (Arthrex) is attached to the tendon and is inserted into the bone tunnel. The screw is inserted until flush with the anterior cortex, while the tendon stays reduced deep into the tunnel. The nonabsorbable suture is then tied. This procedure would always be the last procedure of the case.

Postoperative Management

To encourage healing of the biceps tendon in its new insertion site on the humerus, patients wore a sling and were allowed active assistive elbow flexion for the first 4 weeks. From weeks 4 to 12, the sling was discontinued and active range of motion of the elbow was initiated in all planes of motion. Rotator cuff, deltoid, and parascapular muscle strengthening was begun, starting with isometrics and progressing to elastic band resistance. From week 12 to 6 months, resistive strengthening of the elbow musculature was initiated, starting with isometrics and increasing to elastics bands and handheld weights. In the case of concomitant rotator cuff repair, a postoperative protocol consisting of 6 to 8 weeks in the sling, passive range of motion for 6 weeks, active assistive progressing to active motion from 6 to 12 weeks, and initiation of strengthening at 12 weeks was used.

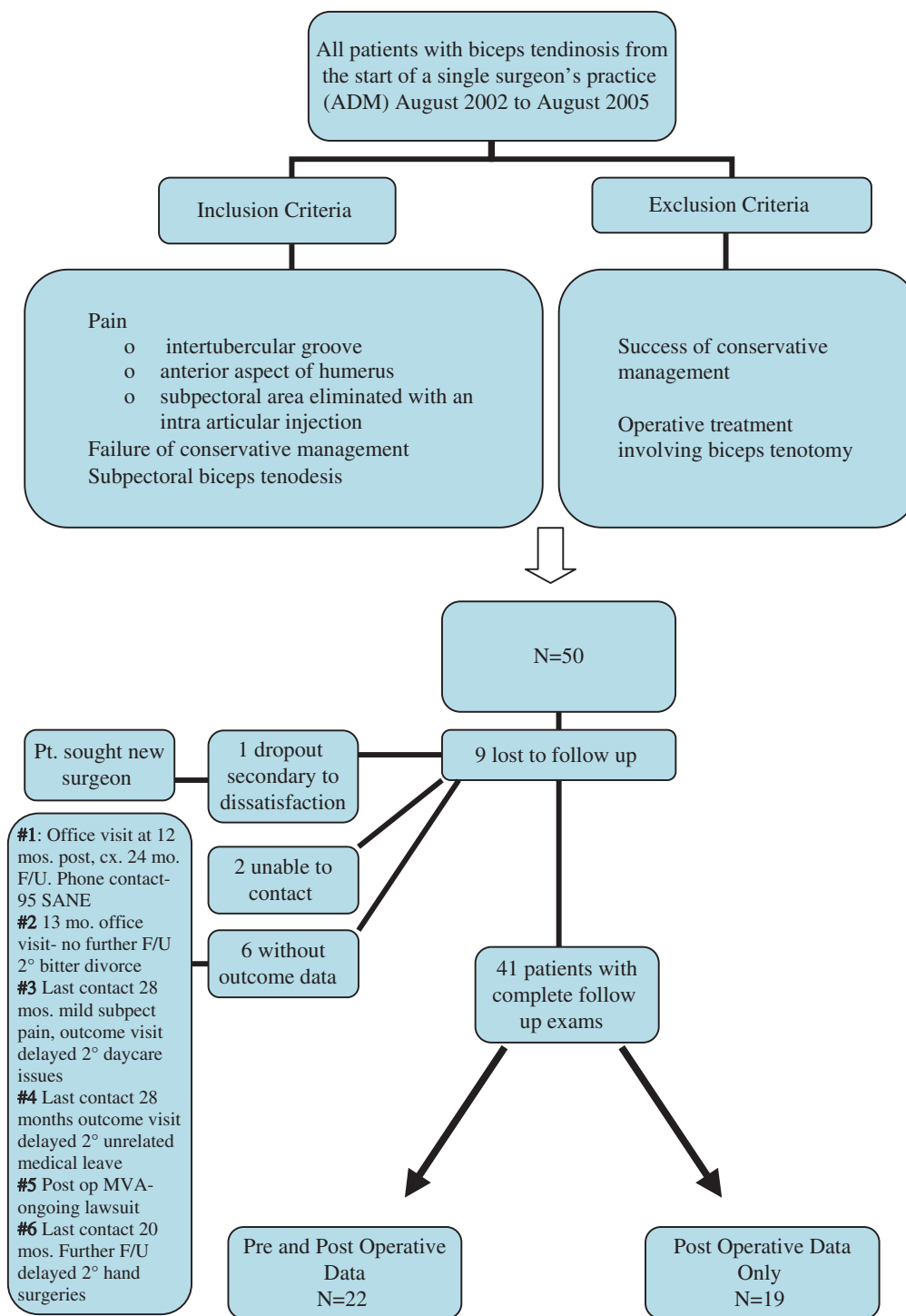


Figure 1. Flow of patients through the study. Pt, patient; F/U, follow-up; SANE, Single Assessment Numeric Evaluation; MVA, motor vehicle accident; cx, cancelled.

Outcome Assessment

Patients who underwent a subpectoral biceps tenodesis were evaluated using the Rowe score,²⁰ American Shoulder and Elbow Surgeons (ASES) score,¹⁸ Simple Shoulder Test

(SST),¹² Constant Murley (CM) score,⁴ and Single Assessment Numeric Evaluation (SANE) score.²¹ All follow-up examinations were performed at a minimum of 1 year postoperatively. Additional measures included a verbal 0 to 10 scale for pain to palpation in the intertubercular groove, pain to

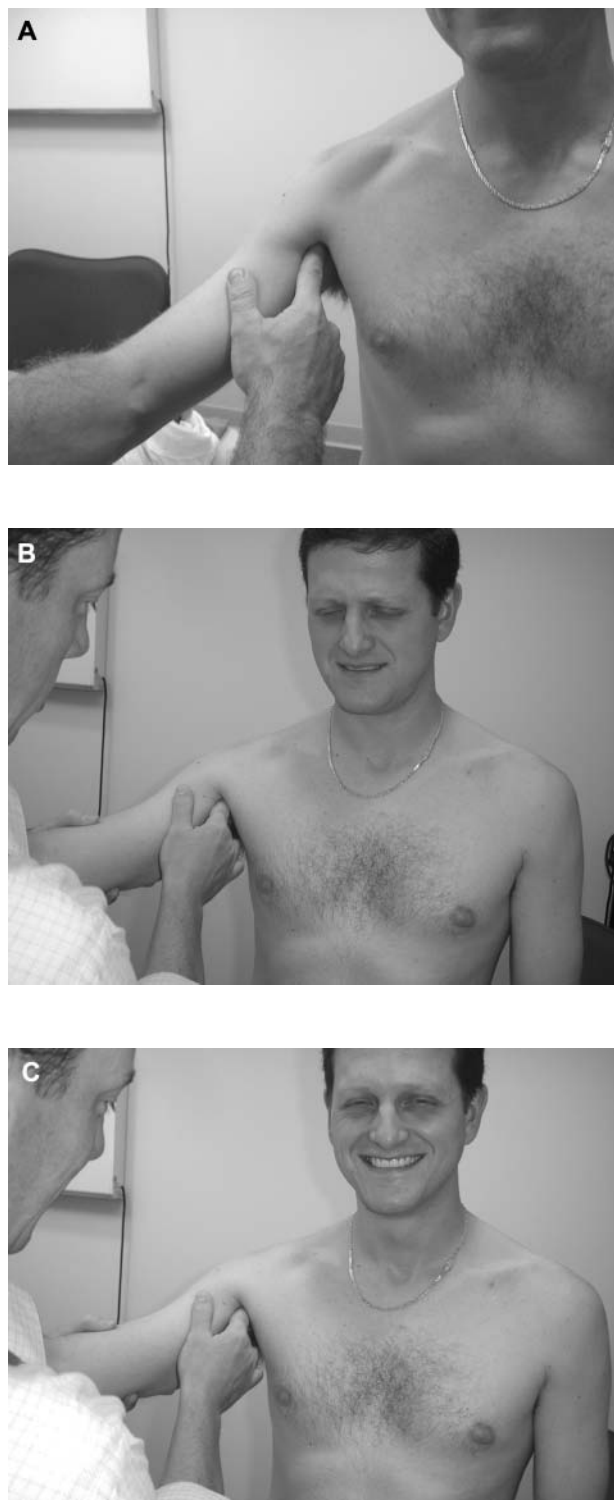


Figure 2. A, examiner palpates biceps under the pectoralis muscle tendon unit. B, pain elicited is considered a positive test indicating biceps tendinosis. C, after injection, pain in the subpectoral area is removed, implicating the biceps as a possible source of pain.

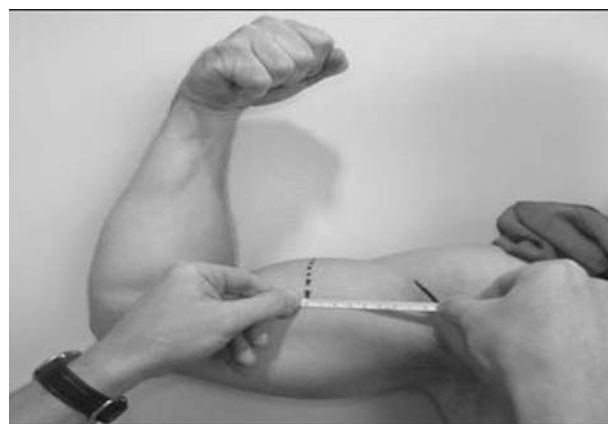

Figure 3. Biceps apex distance (measurement from the medial border of the pectoralis tendon to the apex of the biceps, compared bilaterally and expressed as a difference between the 2 arms).

palpation in the subpectoral triangle, pain to palpation in the anterior aspect of the humerus, and biceps apex distance (measurement from the medial border of the pectoralis tendon to the apex of the biceps compared bilaterally and expressed as a difference between the 2 arms [Figure 3]). This was measured by positioning the patient in 90° of shoulder abduction and 90° of elbow flexion. The apex of the biceps was located and marked by instructing the patient to produce an isometric contraction of the biceps muscle. The medial border of the pectoralis tendon was then located and marked. A tape measure was used to record the distance between the apex and pectoralis tendon. This process was then repeated on the opposite side.

Preoperative data were collected by the primary surgeon (A.D.M.), and postoperative data were collected by both an independent observer (M.P.C.) and the primary surgeon.

Statistical Analysis

All data were analyzed using SPSS 12 software (SPSS Science Inc, Chicago, Illinois). Descriptive statistics were reported using means and standard deviation where appropriate. A 2-sample equal variance *t* test and paired sample *t* test were used to explore pre- and postoperative outcome measures. A 2-sample uneven variance *t* test was conducted to evaluate whether patients with rotator cuff lesions differed in their clinical outcomes. The α level for all statistics was set at .05.

RESULTS

Between November 2002 and August 2005, 50 patients underwent subpectoral biceps tenodesis. Complete follow-up examinations were performed in 41 of 50 (82%); there were 16 women and 25 men (mean age, 50 years). Twenty-four

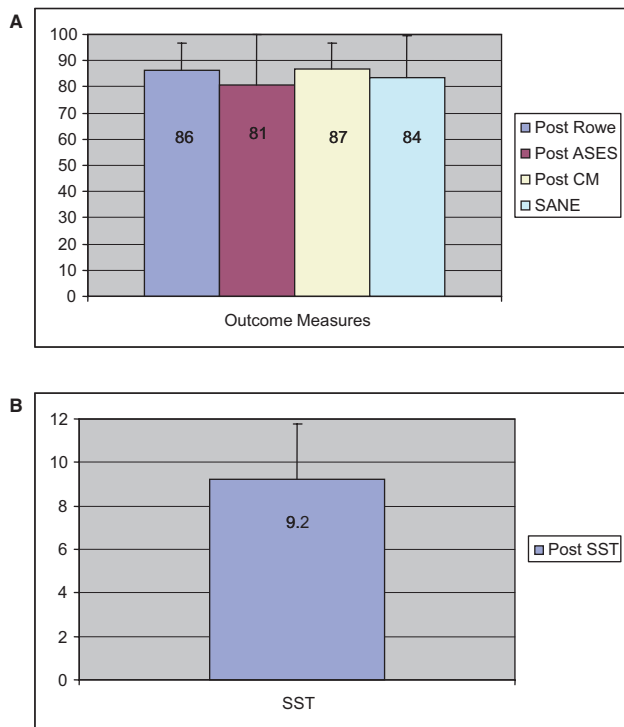


Figure 4. A, postoperative clinical outcome scores at a mean follow-up of 29 months. ASES, American Shoulder and Elbow Surgeons; CM, Constant Murley; SANE, Single Assessment Numeric Evaluation. B, Simple Shoulder Test (SST) at a mean follow-up of 29 months.

patients (59%) had arthroscopic rotator cuff repairs with subacromial decompression (SAD). Of these 24, 1 patient was a revision case and another patient had a Bankart repair with anterior capsulorrhaphy performed concomitantly. Eight (20%) had SAD with glenohumeral or rotator cuff debridement, 4 (10%) had distal clavicle excisions and SAD, 2 (5%) had glenohumeral debridements and coracoplasty, 2 (5%) underwent superior labrum anterior and posterior (SLAP) repairs, and 1 (2%) had an open excision of a lipoma.

Follow-up averaged 29 months (range, 12-49). The mean scores were 86 out of 100 (range, 67-100), Rowe; 81 of 100 (range, 32-100), ASES; 9 out of 12 (range, 3-12), SST; 87 of 100 (range, 67-100), CM; and 84 out of 100 (range, 50-100), SANE (Figure 4). There was 1 failure as demonstrated by pull-out of the tendon from the bone tunnel resulting in a "Popeye" deformity on physical examination. The mean value for biceps apex distance was 0.15 cm (range, 0-3) with 35 of 41 demonstrating no difference on physical examination (Figure 5). No patients (n = 0 of 41) reported pain in the intertubercular groove. Thirty-eight of 41 patients (93%) had no pain in the subpectoral triangle. The remaining 3 patients had a mean pain score of 1.1 (range, 0.5-1.9) out of 10. Thirty-two of 41 patients (78%) reported no episodes of pain in the anterior aspect of the humerus. The mean pain score for the remaining 9 was 1.8 (range, 1-4) out of 10 (Figure 6).

Twenty-three of 41 patients had complete pre- and postoperative examinations. Preoperative examinations included

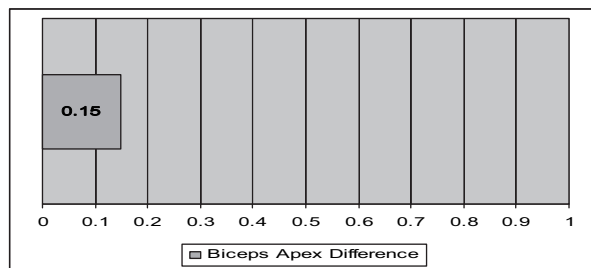


Figure 5. The mean value for biceps apex difference measured in centimeters. Thirty-four of 41 demonstrated no difference on physical examination.

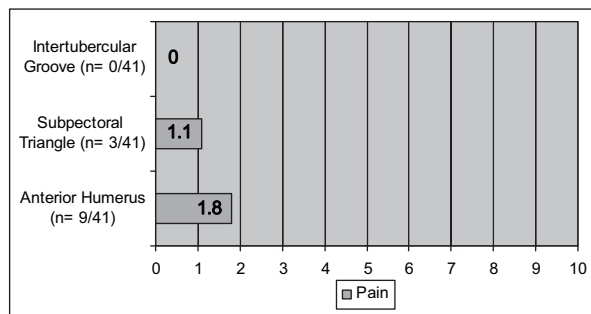


Figure 6. Mean pain scores of those with pain at follow-up.

the Rowe, ASES, and SST scores. In this group of 23 patients, a paired sample *t* test was used to compare preoperative outcome measures and postoperative outcome measures. All clinical outcome measures demonstrated a statistically significant improvement at follow-up when compared with the preoperative scores. A 2-sample even variance *t* test was conducted to determine if the remaining 18 patients (43%) with postoperative data only were different from those with complete examinations. No clinical outcome measures demonstrated any difference (Rowe, *P* = .92, ASES, *P* = .54; SST, *P* = .94; CM, *P* = .64, and SANE, *P* = .66). The preoperative and postoperative scores are presented in Figure 7.

Thirty-one patients had identified lesions of the rotator cuff at the time of arthroscopy. Of these patients, 17 (55%) were repaired using a single row of anchors, 6 (19%) were repaired using a double-row technique, 7 (23%) had SAD or debridement, and 1 patient (3%) underwent a revision rotator cuff repair with margin convergence sutures. This is graphically depicted in Figure 8. A 2-sample uneven variance *t* test was conducted to evaluate whether patients with rotator cuff lesions differed in their clinical outcomes. The mean ASES score in patients without rotator cuff lesion (89.2 ± 10.3) was significantly greater than the mean ASES for those with rotator cuff lesion (78.0 ± 21.0) (*P* = .0324). The mean SST score in patients without rotator cuff lesion (10.6 ± 1.5) was significantly greater than the mean ASES score for those with rotator cuff lesion (8.8 ± 2.7) (*P* = .0132). The mean Rowe (*P* = .0572), CM (*P* = .1661), and SANE (*P* = .4668) scores were not statistically significantly different. These data are graphically depicted in Figure 9.

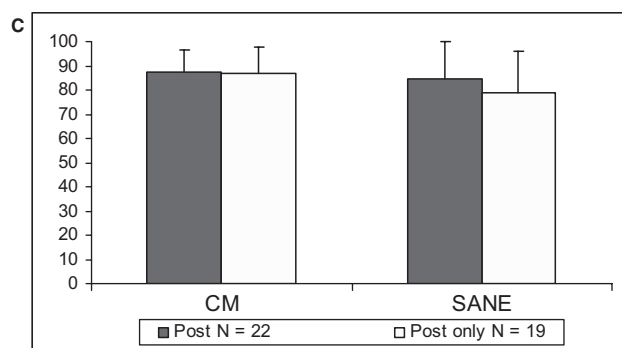
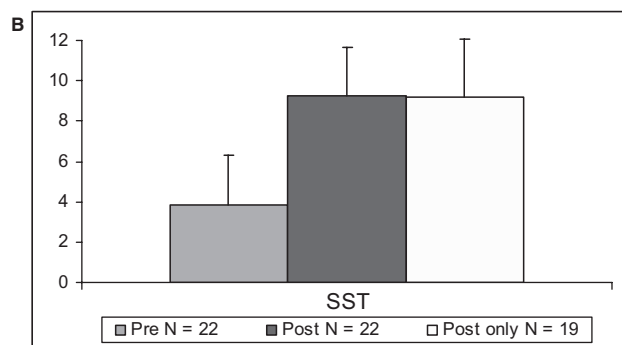
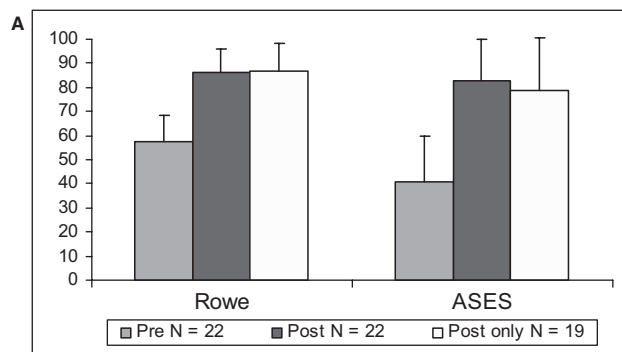


Figure 7. A, pre- and postoperative clinical outcome score comparison. ASES, American Shoulder and Elbow Surgeons. B, pre- and postoperative Simple Shoulder Test (SST) comparison. C, pre- and postoperative clinical outcome score comparison. CM, Constant Murley; SANE, Single Assessment Numeric Evaluation.

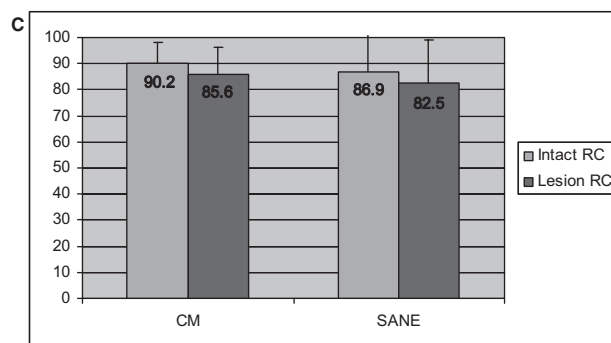
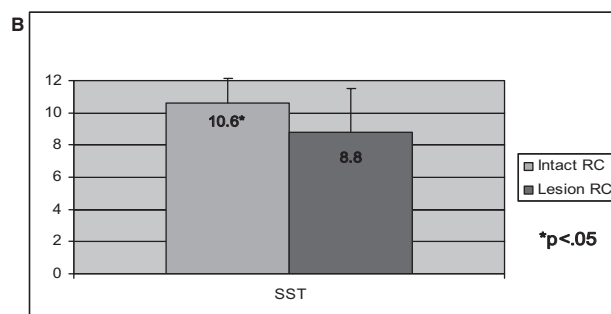
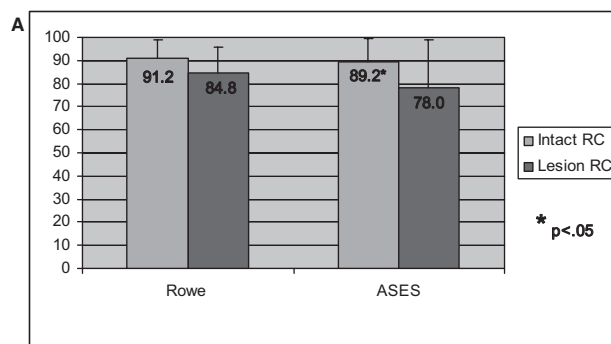


Figure 9. A, comparison of clinical outcome scores between patients with rotator cuff (RC) lesion and those without. B, comparison of Simple Shoulder Test (SST) scores between patients with RC lesion and those without. C, comparison of clinical outcome scores between patients with rotator cuff pathology and those without. CM, Constant Murley; SANE, Single Assessment Numeric Evaluation.

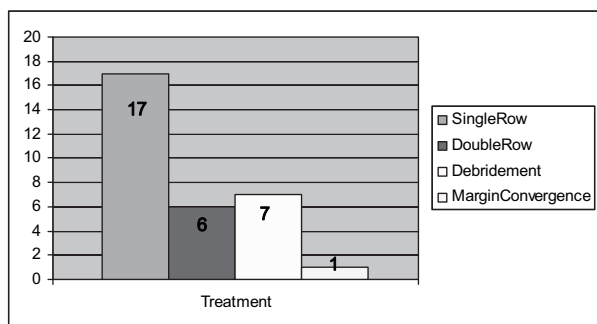


Figure 8. Treatment of identified rotator cuff lesions.

DISCUSSION

This is a prospective case series of 1 surgeon’s experience with subpectoral biceps tenodesis using an interference screw for the management of biceps tendinosis. It provides positive clinical data that combine well with the technical and biomechanical studies that have been previously reported. It also includes the learning curve of the surgeon, which is very small as evidenced by the positive data. We have nearly complete capture of all patients, including those “lost” to follow-up who had verbal questionnaires and were seen in the office for other reasons. Because of organizational

flaws early in the study period, some of the prospective data were not collected and thus pre- and postoperative comparisons were only presented on those 23 (56%) that were complete. Because the purpose of this study was to report on an entire group of patients from 1 surgeon's practice we decided to present all of our data. The follow-up outcome measures for the pre- and postoperative and the postoperative only are essentially the same (Figure 7). The high *P* values generated with the 2-sample even variance *t* test that was conducted to compare these groups further supports the validity of the postoperative only findings.

Several authors have examined the outcomes associated with surgical treatment of biceps lesions. Crenshaw and Kilgore⁵ reviewed the results of 3 different techniques for tenodesis of the biceps, finding 90% good to excellent results after 1 year. The most striking finding of their case series was relief of pain. Froimson and Oh⁸ reported the results of their keyhole tenodesis technique, finding good to excellent results in all 11 cases studied. Contrary to the findings of Crenshaw and Kilgore, Becker and Cofield¹ found that half of the patients in their case series had unsatisfactory results upon follow-up. Their experience led them to conclude that those refractory to treatment were likely to exhibit subacromial impingement with a rotator cuff tear. This seems to agree with the findings of Dines et al,⁷ who attributed clinical failures in their case series to additional or undiagnosed lesions. Berlemann and Bayley² found good to excellent results on long-term follow-up in a group of patients who had undergone keyhole biceps tenodesis. Our findings are in agreement with these previously reported studies. In our study, all patients (41 of 41) reported relief of preoperative biceps tendinosis symptoms, and good to excellent results were seen in all patients, including the 1 failure.

The diagnosis of proximal biceps tendon disease is challenging because of frequently associated lesions and the proximity of the rotator cuff, acromioclavicular joint, superior labrum, and anterior capsule. This differs from pain due to rotator cuff disease or lesions of the subacromial space, which is often localized to the anterolateral or lateral aspect of the shoulder. The shoulder pain associated with biceps tendinosis "radiates" down the anterior arm into the biceps muscle and tenderness over the intertubercular groove and subpectoral triangle are often present. In this study, all patients presented with these symptoms on preoperative examination. On follow-up examination, pain in the intertubercular groove was eliminated in all patients. Three of 41 had mild discomfort (1.1 out of 10) in the subpectoral triangle upon palpation and 9 of 41 reported only mild discomfort (1.8 out of 10) in the anterior aspect of the humerus. With the exception of the failure, none of the patients reporting symptoms required or elected further treatment. All 9 patients reporting pain in the anterior aspect of the humerus described a diffuse discomfort, noting that the preoperative radiating arm pain had been eliminated. Of these 9 patients, 8 had identified lesions of the rotator cuff at the time of surgery. Concomitant rotator cuff lesions may have affected the amount of anterior arm symptoms seen postoperatively. These findings suggest that the procedure was effective in alleviating preoperative biceps tendinosis symptoms.

One of the advantages of performing a biceps tenodesis rather than a biceps tenotomy is maintaining the length-tension relationship of the biceps muscle by establishing a new origin of biceps attachment at the appropriate length to prevent muscle atrophy.¹⁹ We attempted to quantify the anatomic tensioning of the biceps by creating a measurement called the biceps apex distance. This technique, as previously described, evaluates the symmetry of the biceps during isometric contraction by comparing the involved side to the uninvolved side (perfect score = 0). In our series of patients, subpectoral biceps tenodesis was effective in restoring biceps symmetry in 35 of the 41 patients. Of the remaining 6, 1 failed by pull-out of the tendon and 5 demonstrated minimal changes in apex distance (mean, 0.15 cm) on physical examination.

Proximal biceps pathologic changes are more commonly associated with rotator cuff disease, and are infrequently an isolated entity. In our case series, 31 patients had isolated lesions of the rotator cuff at the time of arthroscopy. These patients had statistically significant lower ASES and SST scores, suggesting that rotator lesions present at the time of biceps tenodesis may have a negative effect on the functional outcome achieved postoperatively.

Limitations of this study are that it is a case series with no control group. An independent observer did not perform all of the postoperative testing due to patient scheduling difficulties and insurance issues. Although subjective strength testing demonstrated normal strength in all participants, no objective measures of isokinetic strength or force production were captured. Not all of the prospective data were collected due to organizational flaws early in the study period.

Subpectoral biceps tenodesis with an interference screw is a biomechanically sound and anatomically reproducible procedure. This also appears to be true clinically. There were good to excellent results in all patients. In our experience, this procedure was able to eliminate biceps tendinosis symptoms. It was able to re-create the normal biceps contour (clinically insignificant biceps apex difference) and anatomic length-tension relationship of the muscle (no reported spasm), and to establish subjective strength maintenance. In conclusion, subpectoral biceps tenodesis with an interference screw is a viable treatment option for patients with symptomatic biceps tendinosis.

ACKNOWLEDGMENT

Unbiased research support provided by Arthrex Inc (Naples, Florida).

REFERENCES

1. Becker DA, Cofield RH. Tenodesis of the long head of the biceps brachii for chronic bicipital tendonitis: long-term results. *J Bone Joint Surg Am.* 1989;71:376-381.
2. Berlemann U, Bayley I. Tenodesis of the long head of biceps brachii in the painful shoulder: improving results in the long term. *J Shoulder Elbow Surg.* 1995;4:429-435.

3. Boileau P, Krishnan SG, Coste JS, Walch G. Arthroscopic biceps tenodesis: a new technique using bioabsorbable interference screw fixation. *Arthroscopy*. 2002;18:1002-1012.
4. Constant CR, Murley AHG. A clinical method of functional assessment of the shoulder. *Clin Orthop Relat Res*. 1987;214:160-164.
5. Crenshaw AH, Kilgore WE. Surgical treatment of bicipital tenosynovitis. *J Bone Joint Surg Am*. 1966;48:1496-1502.
6. Depalma AF, Callery GE. Bicipital tenosynovitis. *Clin Orthop*. 1954;3:69-85.
7. Dines D, Warren RF, Inglis AE. Surgical treatment of the long head of the biceps. *Clin Orthop Relat Res*. 1982;164:165-171.
8. Froimson AI, Oh I. Keyhole tenodesis of biceps origin at the shoulder. *Clin Orthop Relat Res*. 1975;112:245-249.
9. Gerber C, Terrier F, Ganz R. The role of the coracoid process in the chronic impingement syndrome. *J Bone Joint Surg Br*. 1985;67:703-708.
10. Gilcreest EL. Dislocation and elongation of the long head of the biceps brachii. An analysis of six cases. *Ann Surg*. 1936;104:118-138.
11. Hitchcock HH, Bechtol CO. Painful shoulder: observation on the role of the tendon of the biceps brachii in its causation. *J Bone Joint Surg*. 1948;30:263-273.
12. Lippitt S, Harryman DI, Matsen F. A practical tool for evaluating shoulder function: the simple shoulder test. In: Matsen FA III, Fu FH, Hawkins RJ, eds. *The Shoulder: A Balance of Mobility and Stability*. Rosemont, IL: American Academy of Orthopaedic Surgeons; 1993:501-518.
13. Lippmann RK. Frozen shoulder, periartthritis, bicipital tenosynovitis. *Arch Surg*. 1943;47:283-296.
14. Mazzocca AD, Bicos J, Santangelo S, Romeo AA, Arciero RA. The biomechanical evaluation of four fixation techniques for proximal biceps tenodesis. *Arthroscopy*. 2005;21:1296-1306.
15. Mazzocca AD, Noerdlinger MA, Romeo AA. Mini open and subpectoral biceps tenodesis. *Oper Tech Sports Med*. 2003;11:24-31.
16. Michele AA. Bicipital tenosynovitis. *Clin Orthop*. 1960;18:261-267.
17. Neer CS. Impingement lesions. *Clin Orthop Relat Res*. 1983;173:70-77.
18. Richards RR, An K-N, Bigliani LU, et al. A standardized method for the assessment of shoulder function. *J Shoulder Elbow Surg*. 1994;3:347-352.
19. Romeo AA, Mazzocca AD, Tauro JC. Arthroscopic biceps tenodesis. *Arthroscopy*. 2004;20:206-213.
20. Rowe CR, Patel D, Southmayd WW. The Bankart procedure: a long term end-result study. *J Bone Joint Surg Am*. 1978;60:1-16.
21. Williams GN, Gangel TJ, Arciero RA, Uhorchak JM, Taylor DC. Comparison of the single assessment numeric evaluation method and two shoulder rating scales: outcomes measures after shoulder surgery. *Am J Sports Med*. 1999;27:214-221.