

# Suprascapular Neuropathy

Anthony A. Romeo, MD, D. Daniel Rotenberg, MD, and Bernard R. Bach, Jr, MD

## Abstract

*Suprascapular neuropathy is an uncommon cause of shoulder pain and weakness and therefore may be overlooked as an etiologic factor. The suprascapular nerve is vulnerable to compression at the suprascapular notch as well as at the spinoglenoid notch. Other causes of suprascapular neuropathy include traction injury at the level of the transverse scapular ligament or the spinoglenoid ligament and direct trauma to the nerve. Sports involving overhead motion, such as tennis, swimming, and weight lifting, may result in traction injury to the suprascapular nerve, leading to dysfunction. The diagnosis of suprascapular neuropathy is based on clinical findings and abnormal electrodiagnostic test results, after the exclusion of other causes of shoulder pain and weakness. Magnetic resonance imaging may provide an anatomic demonstration of nerve entrapment and muscle atrophy. With this modality, ganglion cysts are recognized with increasing frequency as a source of external compression of the suprascapular nerve. Without evidence of a discrete lesion compressing the nerve, nonoperative treatment should include physical therapy and avoidance of precipitating activities. When nonoperative treatment fails to alleviate symptoms or when a discrete lesion such as a ganglion cyst is present, surgical decompression is warranted. Decompression gives reliable pain relief, but recovery of shoulder function and restoration of atrophied muscle tissue may be incomplete.*

**J Am Acad Orthop Surg 1999;7:358-367**

Common causes of shoulder pain and dysfunction include rotator cuff tears, impingement syndrome, acromioclavicular arthrosis, instability, and cervical disk disease. Suprascapular neuropathy also results in pain and shoulder dysfunction. However, due to the infrequency of its occurrence, suprascapular neuropathy may be overlooked as the cause of symptoms.

Extrinsic compression or traction on the suprascapular nerve can result in suprascapular neuropathy. Compression of the nerve may occur at two distinct locations: the suprascapular notch and the spinoglenoid notch. Traction injuries to the suprascapular nerve

most commonly occur at the suprascapular notch, where the nerve is tethered by the transverse scapular ligament. Kopell and Thompson<sup>1</sup> initially described suprascapular neuropathy at the suprascapular notch in 1959. In 1982, Aiello et al<sup>2</sup> differentiated suprascapular nerve entrapment at the spinoglenoid notch from entrapment at the suprascapular notch. If surgical treatment is indicated, it is essential to determine the exact location of the pathologic changes.

Extrinsic compression of the suprascapular nerve by ganglion cysts can occur at the spinoglenoid notch or, less commonly, at the suprascapular notch. These cysts may originate from the transverse

scapular ligament, the fibrous tissue of the scapula, or the glenohumeral joint. Magnetic resonance (MR) imaging of the shoulder is highly sensitive and specific in demonstrating the presence and size of ganglia.<sup>3</sup>

## Anatomy

The suprascapular nerve is a motor nerve that arises from the upper trunk of the brachial plexus formed by the C5 and C6 roots, occasionally with a contribution from the C4 root. The nerve passes laterally across the posterior cervical triangle to reach the scapular notch. The nerve travels in close proximity to the posterior border of the clavicle.<sup>4,5</sup>

*Dr. Romeo is Assistant Professor of Orthopaedic Surgery, Rush Medical College, and Attending Surgeon, Department of Orthopaedic Surgery, Rush-Presbyterian-St. Luke's Medical Center, Chicago. Dr. Rotenberg is Fellow, Department of Orthopaedic Surgery, Section of Sports Medicine, Rush-Presbyterian-St. Luke's Medical Center. Dr. Bach is Professor of Orthopaedic Surgery, Rush Medical College, Chicago; and Director of Sports Medicine, Rush-Presbyterian-St. Luke's Medical Center.*

*Reprint requests: Dr. Bach, Department of Orthopaedic Surgery, Rush-Presbyterian-St. Luke's Medical Center, Suite 1063, 1725 W. Harrison Street, Chicago, IL 60612.*

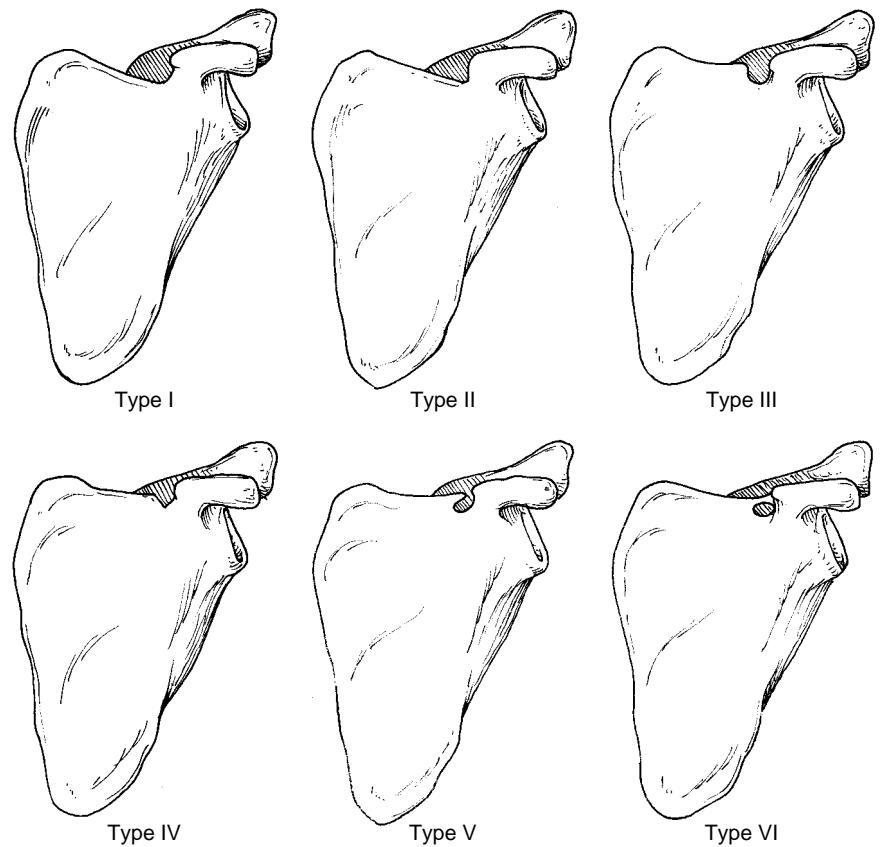
*Copyright 1999 by the American Academy of Orthopaedic Surgeons.*

The suprascapular notch occurs in a variety of different shapes (Fig. 1).<sup>6,7</sup> A narrowed or closed notch may place the nerve at risk for injury. Traction to the shoulder may cause localized stretching of the suprascapular nerve at the notch as a result of its confinement under the transverse scapular ligament or within the osseous architecture. This insult can lead to neurapraxia or axonotmesis.

The notch is enclosed by the transverse scapular ligament, which is partially or completely bridged by bone in 12% to 23% of the population.<sup>7,8</sup> The suprascapular nerve passes through the notch and beneath the transverse scapular ligament and then bifurcates into two main branches.<sup>9,10</sup> The suprascapular artery and vein pass superficial to this ligament (Fig. 2). The nerve supplies one or two motor branches to the supraspinatus muscle and returns sensory fibers from the glenohumeral joint, the acromioclavicular joint, and the coracoacromial ligament.<sup>9,10</sup> A cutaneous branch of the suprascapular nerve that supplies sensation in the same area of the lateral deltoid as the axillary nerve may be present in up to 15% of the population. Despite this variation, the suprascapular nerve is considered a predominantly motor nerve.

In a study of 105 cadaver scapulae, Bigliani et al<sup>10</sup> found that on average the distance from the supraglenoid tubercle to the nerve at the suprascapular notch was 3.0 cm, and the distance from the glenoid rim to the suprascapular nerve at the base of the scapular spine was 1.8 cm (Fig. 3). After traversing the suprascapular fossa, the nerve descends around the lateral margin of the scapular spine (spinoglenoid notch) to supply two or more branches to the infraspinatus.<sup>9,10</sup>

A spinoglenoid ligament (inferior transverse scapular ligament) at the level of the spinoglenoid

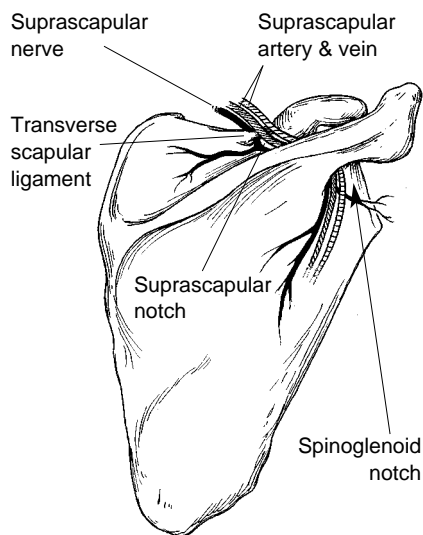


**Fig. 1** Classification of abnormalities of the suprascapular notch. Rengachary et al<sup>7</sup> examined 211 cadaver scapulae and classified abnormalities into six types. In type I, the entire superior border of the scapula shows a depression (8% of specimens). In type II, there is a wide, blunted, V-shaped notch (31%). In type III, the notch is symmetrical and U-shaped (48%). In type IV, there is a very small V-shaped notch (3%). Type V is similar to type III but with partial ossification of the medial portion of the transverse scapular ligament (6%). In type VI, the transverse scapular ligament is completely ossified, resulting in a foramen of variable size (4%). (Adapted with permission from Rengachary SS, Burr D, Lucas S, Hassanein KM, Mohn MP, Matzke H: Suprascapular entrapment neuropathy: A clinical, anatomical, and comprehensive study—Part 2. Anatomical study. *Neurosurgery* 1979;5:447-451.)

notch has been reported with variable prevalence and morphology. In one study,<sup>11</sup> 75 cadaver shoulders were examined specifically for the presence of a spinoglenoid ligament, defined as a fibrous connective tissue band extending from the lateral aspect of the root of the spine of the scapula to the margin of the glenoid process. The ligament was present in only 2 (3%) of the shoulders, and 10 (13%) shoulders demonstrated a thickened aponeurosis that did not extend to the neck of the glenoid. In another

cadaver dissection study,<sup>12</sup> the presence of a spinoglenoid ligament was demonstrated in 14 of 23 shoulders (60%). In addition, the combined motion of cross-body adduction and internal rotation resulted in tightening of the ligament and compression of the nerve under the ligament.

Recently, 112 shoulders from 76 cadavers were evaluated for the presence of a spinoglenoid ligament.<sup>13</sup> The ligament was classified into two types: type I, a thin fibrous band, and type II, a distinct liga-



**Fig. 2** The suprascapular nerve passes through the scapular notch below the transverse scapular ligament. The suprascapular artery and vein pass over the ligament and course lateral to the nerve.

ment. The authors did not find a ligament in 20% of the specimens, but 60% demonstrated a type I ligament, and 20% demonstrated a type II ligament. Therefore, 80% of the specimens had some form of a fibroosseous canal at the level of the spinoglenoid notch. The clinical relevance of the spinoglenoid ligament and its role in suprascapular neuropathy remain uncertain, but the ligament could act as a site of traction with overhead activities, and it may limit advancement of the infraspinatus during repair of massive rotator cuff tears.<sup>13</sup>

In a study of 31 shoulders in 18 cadavers, Warner et al<sup>9</sup> showed that the suprascapular nerve continues around the spinoglenoid notch an average of 2.1 cm away from the posterior rim of the glenoid. The average distance from the posterior corner of the acromion to the suprascapular nerve at the spinoglenoid notch is approximately 4.5 cm.

The suprascapular artery and vein run parallel to the nerve. At the level of the scapular notch, the

vessels course over the transverse scapular ligament. However, a prominent branch of the vessels may be found under the transverse scapular ligament. The vessels generally stay lateral to the nerve, closer to the glenoid rim.

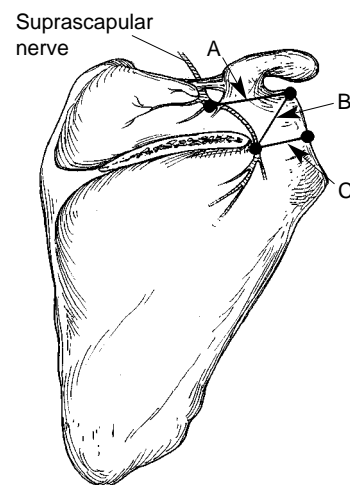
### Pathophysiology

Suprascapular neuropathy can occur as a result of traction, direct trauma, or extrinsic compression or as part of a more generalized brachial plexus disorder. Traction of the suprascapular nerve can occur at the suprascapular or spinoglenoid notch secondary to repetitive microtrauma, primarily from overhead activities such as those involved in tennis, volleyball, and weight lifting. Repetitive microtrauma may lead to direct injury to the nerve or to indirect injury by affecting the vascular supply to the nerve. Intimal damage to the axillary or suprascapular artery may lead to microemboli that become trapped in the vasa nervorum, leading to ischemic injury to the suprascapular nerve.<sup>14</sup> Direct trauma or indirect trauma during glenohumeral dislocation, proximal humerus fracture, or scapular fracture may also result in suprascapular neuropathy.<sup>15,16</sup> Iatrogenic injury to the suprascapular nerve has been reported as a consequence related to distal clavicle resection, positioning during spine surgery, transglenoid arthroscopic anterior shoulder stabilization, shoulder arthrodesis, or procedures utilizing the posterior approach to the shoulder, such as posterior shoulder stabilization.<sup>4,17</sup>

Repetitive microtrauma or a single traumatic event is more likely to cause suprascapular neuropathy at the level of the suprascapular notch. At this site, the nerve has little translational freedom as it angles around the confined space of the suprascapular notch.<sup>8</sup> This angled

pathway and limited mobility predispose the nerve to mechanical stretching, which may be exacerbated by extreme positions of scapular depression, retraction, or abduction.

Compression by a ganglion cyst or tumor is also a cause of suprascapular neuropathy, particularly at the level of the spinoglenoid notch.<sup>18</sup> The fixed position of the suprascapular nerve, combined with the close proximity of the rotator cuff muscles, makes the nerve susceptible to compression by even small cysts. These ganglia may develop when labral or capsular tears allow synovial fluid to be forced into the tissues, creating a one-way-valve effect. A similar mechanism by which meniscal tears lead to meniscal cysts of the knee has been widely accepted, which has led to the belief that many shoulder ganglion cysts are the direct result of a capsulo-



**Fig. 3** Relationship of the suprascapular nerve to osseous landmarks (viewed from posterior). In a study of 105 cadaver scapulae, Bigliani et al<sup>10</sup> found that the average distance from the supraglenoid tubercle to the suprascapular notch (A) was 3.0 cm; from the supraglenoid tubercle to the base of the scapular spine (B), 2.5 cm; and from the midportion of the posterior glenoid rim to the base of the scapular spine (C), 1.8 cm. (Adapted with permission from Bigliani LU, Dalsey RM, McCann PD, April EW: An anatomical study of the suprascapular nerve. *Arthroscopy* 1990;6:301-305.)

labral injury.<sup>19</sup> In a retrospective review of the MR imaging studies of 73 patients with evidence of ganglion cysts in the spinoglenoid notch, the images suggested that 89% of the patients had posterior-superior labral tears; however, this was not confirmed by arthroscopy.<sup>20</sup> Other reports have confirmed a high incidence of labral tears observed during arthroscopy done prior to the decompression of the spinoglenoid cyst.<sup>21</sup>

## Presentation and Clinical Examination

Suprascapular neuropathy frequently presents as a poorly localized dull ache over the lateral and posterior aspects of the shoulder associated with weakness of external rotation and abduction, which can mimic rotator cuff or cervical disk disease. The pain and weakness are more severe with pathologic changes at the level of the suprascapular notch than at the spinoglenoid notch. Symptoms can be referred to the lateral aspect of the arm, the ipsilateral side of the neck, or the anterior chest wall. A history of trauma or repetitive use of the shoulder is common. Traumatic injuries may result from a direct impact on the shoulder or from indirect force, such as a fall on an outstretched arm. Many activities that require repetitive use of the shoulder have been associated with suprascapular neuropathy, including volleyball, basketball, dancing, tennis, weight lifting, swimming, heavy labor, and cardiac rehabilitation.<sup>22-25</sup>

Clinical examination usually demonstrates nonspecific findings early in the disease process. With involvement at the level of the suprascapular notch, tenderness may be found in the area bounded by the clavicle and the scapular spine. If there is long-standing neu-

ropathy at this level, diffuse wasting of both the supraspinatus and the infraspinatus occurs, although the deltoid maintains its normal bulk. The strength of active external rotation is diminished, and abduction strength is also affected.

Symptoms are less severe with suprascapular neuropathy at the level of the spinoglenoid notch. Some patients present with painless isolated wasting of the infraspinatus. Vague symptoms may suggest glenohumeral instability, even when the patient is incapable of describing specific mechanical characteristics. In other instances, tenderness over the area of the spinoglenoid notch may be severe. Remarkably, despite atrophy of the infraspinatus, the patient may not demonstrate weakness with external rotation, due to compensation by the posterior deltoid and teres minor.<sup>22</sup> Isolated wasting of the infraspinatus localizes a potential neurologic compression to the area of the spinoglenoid notch. Cross-body adduction may reproduce the patient's symptoms, as may palpation at the notch. Cross-body adduction with the arm extended or internally rotated may cause increased pain in the posterior aspect of the shoulder, but it is important to distinguish whether this pain is from the acromioclavicular joint or from some other source.<sup>23</sup>

The diagnosis of suprascapular neuropathy is based on the symptoms and the findings from physical examination, electrodiagnostic testing, and, more recently, MR imaging. Exclusion of the more common causes of shoulder pain is essential before the patient's symptoms can be ascribed to suprascapular neuropathy. Cervical disk disease typically causes neck pain and radicular symptoms that should be differentiated from isolated suprascapular neuropathy. A diagnostic nerve block can be performed by injecting a local anesthetic into the suprascapular notch. The test is consid-

ered positive if the pain is completely relieved.<sup>2</sup> Suprascapular nerve blocks may be necessary if the diagnosis remains uncertain after electrodiagnostic testing.

Electromyography and nerve conduction studies can provide essential information in the diagnosis and treatment of suprascapular neuropathy. These tests are indicated when the history and physical examination are suggestive of the diagnosis and after other common causes of shoulder pain and weakness have been excluded. A positive electrodiagnostic study will demonstrate a motor loss in the infraspinatus with or without changes in the supraspinatus muscle (depending on the level of the lesion). Denervation potentials, fibrillations, spontaneous activity, and prolonged motor latencies will be noted, along with delayed conduction time from Erb's point to the supraspinatus or infraspinatus. Abnormal electrodiagnostic studies are a common finding in cases of suprascapular neuropathy, but occasionally a false-negative examination in a patient with chronic neuropathy will be misleading, delaying accurate diagnosis.<sup>25</sup> Electromyography will not define the exact nature of the pathologic changes, nor will it always localize the site of compression.

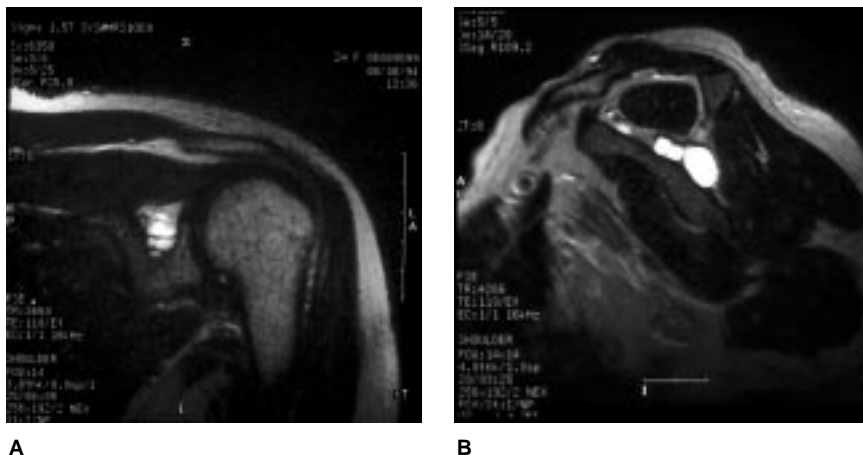
Radiographic evaluation may demonstrate the site of nerve compression. Plain radiographs can show callus formation after scapular fractures and clavicular fractures that involve the suprascapular or spinoglenoid notch. An anteroposterior radiograph of the scapula obtained with the beam directed caudally 15 to 30 degrees offers the best view of the suprascapular notch.<sup>5</sup> Alternatively, the suprascapular notch can be seen on a Stryker notch view. Computed tomography can demonstrate osseous abnormalities affecting the suprascapular nerve, but its utility in de-

picting soft-tissue lesions is limited compared with MR imaging.<sup>3</sup>

Magnetic resonance imaging is the optimal radiologic study for evaluating possible sites of suprascapular nerve entrapment.<sup>3,18,19,26</sup> This modality is useful in identifying the course of the nerve and demonstrating soft-tissue lesions that may affect the nerve. Space-occupying lesions that can cause suprascapular nerve compression (most commonly, ganglion cysts) are easily identified with MR imaging.<sup>18</sup> Typical findings of a ganglion cyst include homogeneity, low signal intensity on T1-weighted images, and high signal intensity on T2-weighted images (Fig. 4, A).<sup>3,19,26</sup> The T2-weighted oblique sagittal view shows the suprascapular nerve as it courses through the supraspinous fossa, around the spinoglenoid notch, and into the infraspinous fossa (Fig. 4, B). This information is important because the surgical approach depends on whether the lesion is confined to the supraspinous fossa or the infraspinous fossa or involves both areas. Magnetic resonance imaging also provides useful information about the rotator cuff and the presence of muscle atrophy. If the MR study is unremarkable but there is shoulder pain and dysfunction of the posterior rotator cuff, electrodiagnostic testing may provide evidence for a diagnosis of suprascapular neuropathy and may localize the most likely site of entrapment.

## Treatment

The initial treatment for suprascapular neuropathy without evidence of a space-occupying lesion should be nonoperative<sup>24</sup> (Fig. 5). In the absence of a lesion causing direct compression of the nerve, most suprascapular neuropathies will resolve completely.<sup>25</sup> Unfortunately, neuropathic symptoms, in-



**Fig. 4** A, Coronal T2-weighted spin-echo MR image demonstrates a large ganglion cyst compressing the suprascapular nerve. B, An oblique sagittal T2-weighted spin-echo MR image demonstrates extension of the ganglion cyst from the supraspinous fossa into the infraspinous fossa.

cluding pain and weakness, may take more than a year to reach maximum improvement. A self-directed home exercise program of physical therapy is prescribed to maintain full glenohumeral motion and to strengthen the rotator cuff muscles, the deltoid, and the periscapular musculature. Special attention should be directed toward establishing proper posture with scapular retraction exercises, as well as strengthening of the trapezius, the rhomboids, and the serratus musculature. Rehabilitation focused on scapular function is beneficial in recovery and may avoid recurrence of the injury.

Operative release of the transverse scapular ligament is indicated for suprascapular nerve entrapment at the suprascapular notch in patients who have not experienced improvements in comfort and strength despite 6 months of nonoperative treatment. Because identification of the condition is frequently delayed, symptoms are often present for more than 6 months before the diagnosis of suprascapular neuropathy is confirmed. This has led some authors to recommend surgical

treatment for suprascapular neuropathy once the diagnosis and the site have been confirmed.<sup>25</sup> Other authors have suggested nonoperative treatment for as long as 1 year after the onset of symptoms when there is no evidence of extrinsic compression of the nerve, as, for example, by a ganglion cyst.<sup>24</sup>

Decompression of the suprascapular nerve at the suprascapular notch is best achieved through a trapezius-splitting approach (Fig. 6). Either the beach-chair or the lateral decubitus position can be utilized. The "saber" skin incision follows Langer's lines over the top of the shoulder beginning at the distal third of the scapular spine and proceeding 2 cm medially to the acromioclavicular joint.<sup>27</sup> Alternatively, a transverse skin incision parallel to the scapular spine can be used, but this incision frequently leads to a less cosmetically acceptable scar.

The trapezius is divided in line with its fibers for a distance of 5 cm, with additional relaxation of the fibers achieved by abducting the arm.<sup>5,27</sup> If necessary, the trapezius can be elevated off the scapular spine for an extensile exposure. The

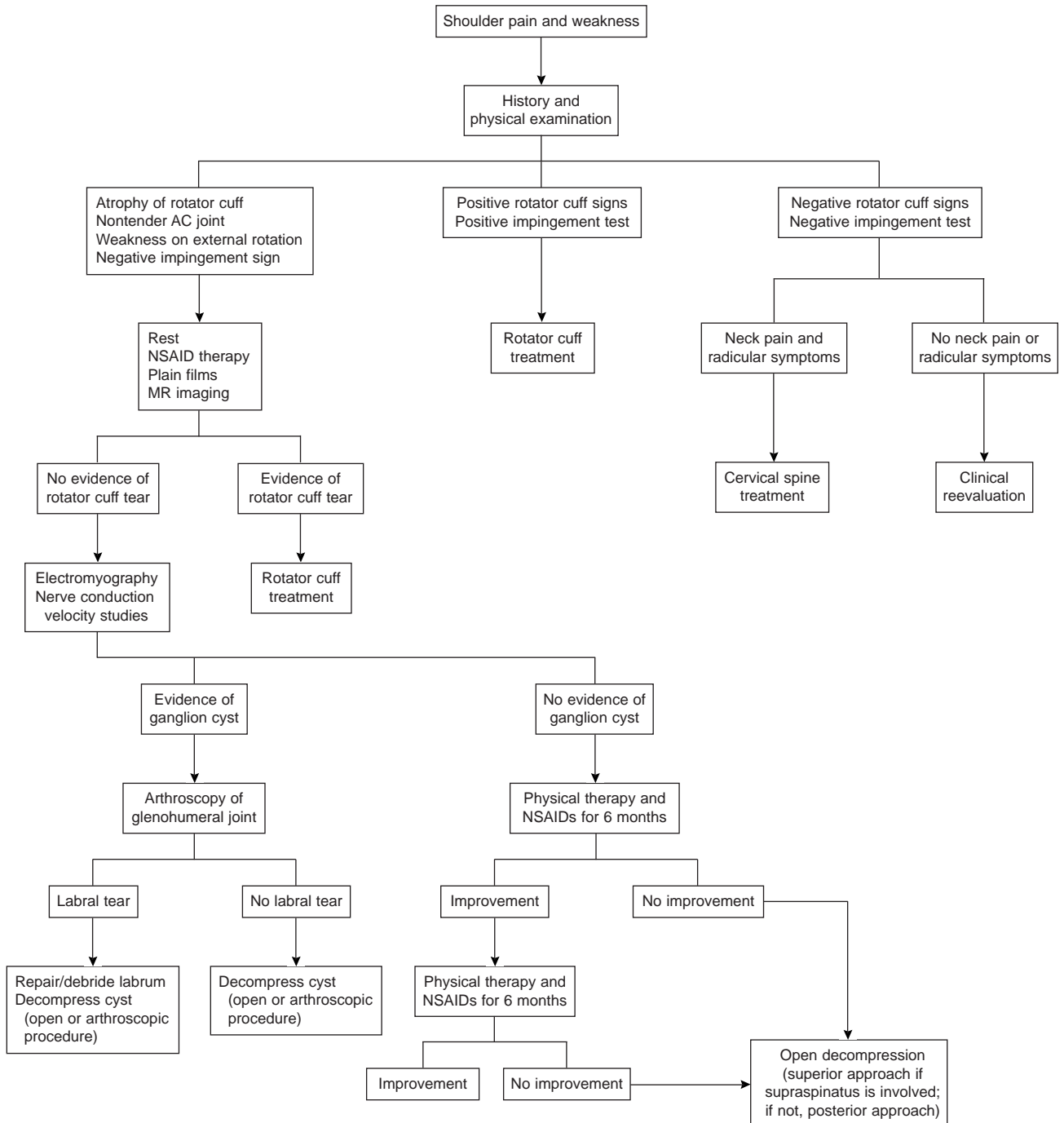


Fig. 5 Algorithm for the management of suprascapular neuropathy. AC = acromioclavicular; NSAID = nonsteroidal anti-inflammatory drug.

supraspinatus muscle is retracted posteriorly to provide access to the suprascapular notch. The suprascapular notch is identified with a small right-angle clamp to protect

the suprascapular nerve. The transverse scapular ligament is transected after gentle retraction of the overlying suprascapular artery and vein. If the suprascapular nerve is still

tethered within the boundaries of the suprascapular notch, additional resection of the medial aspect of the suprascapular notch can be performed. The resected edge of the

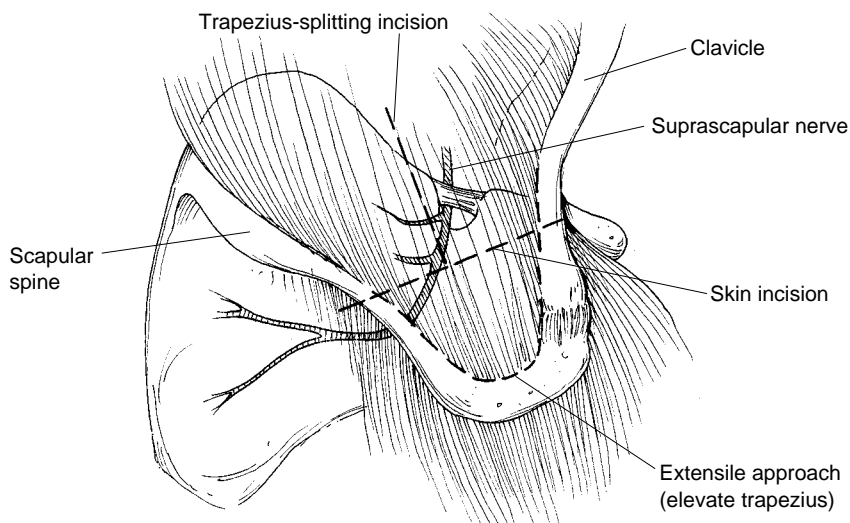


Fig. 6 Superior approach to the suprascapular nerve at the scapular notch.

bone must be smooth at the completion of the procedure.

If the trapezius has been detached from the scapular spine, it should be sutured to bone. When the trapezius has been split, the fibers can be reapproximated with absorbable sutures. An anterior approach is not recommended because of the complex dissection required and the higher risk of neurovascular complications and the relatively poor visualization of the suprascapular nerve posterior to the notch.<sup>5</sup>

Patients with suprascapular neuropathy related to impingement in the spinoglenoid notch may be relatively pain-free at presentation, with infraspinatus atrophy the only objective finding.<sup>22</sup> Nonoperative management is recommended when there is no evidence of extrinsic compression. Ferretti et al<sup>22</sup> reported isolated infraspinatus atrophy in asymptomatic volleyball players, concluding that this lesion represents a benign condition with minimal disability. Black and Lombardo<sup>28</sup> reported that four athletes treated with physical therapy regained full function of the infra-

spinatus over the course of 6 to 12 months. Surgical exploration of the nerve, resection of potentially compressive fibrous tissue, and release of the spinoglenoid ligament (if present) is recommended when there is no improvement after 6 months of nonoperative treatment.

The posterior approach provides direct visualization of the suprascapular nerve at the spinoglenoid notch (Fig. 7). A 5-cm longitudinal skin incision is made in Langer's lines 3 cm medial to the posterolateral corner of the acromion. The deltoid is then split in line with its fibers beginning at the scapular spine. The distal extent of the deltoid split is limited to 5 cm from the posterior acromion; a stay suture is placed at this level to reduce the risk of injury to the axillary nerve. The superior edge of the infraspinatus is identified and retracted inferiorly. A small area of vascular fibrous tissue is encountered posterior to the site of the spinoglenoid notch.<sup>9</sup> Careful dissection through this area will lead to the suprascapular vessels and nerve. Decompression of the suprascapular nerve is completed when

the nerve is visualized from the spinoglenoid notch until it arborizes into its branches for the infraspinatus.

If a ganglion is present, the cyst is excised, and the nerve is evaluated for any residual sources of entrapment, such as a fibrous band or a spinoglenoid ligament. The contents of the cyst as well as the cyst wall should be removed while protecting the neurovascular structures. Although there appears to be a common association between spinoglenoid cysts and glenoid labral tears, decompression of the cyst without exploration of the glenohumeral joint has been associated with excellent results.<sup>29</sup> If a spinoglenoid ligament is identified, it should be excised under direct vision. After decompression of the suprascapular nerve, the infraspinatus muscle is allowed to return to its anatomic position, and the deltoid fascia is reapproximated.

The natural history of ganglion cysts around the glenohumeral joint is unknown, but in general they persist and may gradually enlarge over time.<sup>20</sup> The presence of a ganglion cyst in association with suprascapular neuropathy is most effectively treated with decompression of the cyst and evaluation of the glenoid labrum. Repair of the glenoid labrum may be indicated in more than two thirds of patients with spinoglenoid cysts.<sup>19,20,23</sup> In rare instances, spontaneous resolution of ganglion cysts has been documented with MR imaging.<sup>30</sup> Other causes of shoulder pain and weakness should be considered when the cyst is less than 1 cm in diameter or is located away from the suprascapular nerve.<sup>23</sup>

Image-guided aspiration of ganglia compressing the suprascapular nerve has been reported. In one study, image-guided aspiration was performed in five patients, three of whom were asymptomatic 2 to 13 months after the procedure.<sup>19</sup> Cyst

recurrence was demonstrated at 6 months in one patient. No follow-up data on the last patient were reported. In another study,<sup>20</sup> which reviewed the results in 11 patients treated with needle aspiration, the recurrence rate after a follow-up interval of less than 2 years was 48%. The procedure failed to aspirate the cyst in 18% of cases.<sup>20</sup> Overall, 6 of the 11 patients (54%) were satisfied with the outcome.

Open posterior exploration can be performed, with excision of the ganglion compressing the suprascapular nerve. However, the presence of a spinoglenoid cyst suggests that there may be a labral tear, which is best evaluated and treated with glenohumeral arthroscopy. If a labral tear is identified during arthroscopy, decompression of the cyst is performed after stabilization of the labrum to the glenoid rim.

Iannotti and Ramsey<sup>31</sup> reported the data on three patients with suprascapular neuropathy secondary to a ganglion cyst that was treated with arthroscopic decompression. The cyst was approached through a

superior-posterior capsulotomy of the glenohumeral joint. At the 1-year follow-up, the patients had resolution of symptoms without recurrence of the ganglion on repeat MR imaging. Arthroscopic decompression of the cyst has the advantage of effectively treating associated intra-articular lesions and avoiding the morbidity of an open procedure.

We have arthroscopically decompressed six cysts of various sizes and locations along the path of the suprascapular nerve. Associated labral lesions included three tears that required stabilization and two frayed labra, which were treated with debridement. The ganglion cyst was most commonly at the level of the spinoglenoid notch and extended into the infraspinous fossa. Routine glenohumeral arthroscopy included careful inspection of the superior-posterior labrum. If the labrum was intact, the capsule above the labrum was incised for 2 to 3 cm beginning posterior to the biceps root. Hemostasis and visualization were facilitated by increasing the arthroscopic pump pressure to 50

mm Hg. The same fibrous tissue seen with the open approach was encountered in the area of the spinoglenoid notch.

With our preferred technique, the notch can be palpated with an arthroscopic instrument, which provides a fixed internal landmark that can be correlated with the cyst position as seen on preoperative MR imaging. Another useful landmark is the fibrous raphe between the suprascapular and infraspinous fossae seen lateral to the spinoglenoid notch after incision of the capsule. An accessory posterolateral portal can then be established to approach the spinoglenoid cyst.<sup>31</sup>

An 18-gauge needle is advanced into the glenohumeral joint to determine the proper orientation of the accessory posterolateral portal. If the cyst extends into the suprascapular fossa, an anterosuperior portal is necessary. Through the accessory portal, blunt dissection of the fibrous tissue over the neurovascular structures is performed until the cyst is directly visualized. The suprascapular nerve is in direct contact with the spinoglenoid notch, but the vascular structures will be lateral to the nerve. The cyst is usually posterior to the suprascapular nerve. After decompression of the cyst and removal of the cyst lining, the nerve can be inspected for any additional sites of compression.

## Results of Surgical Treatment

Because of the relative infrequency of the diagnosis of suprascapular neuropathy, there are few series of cases with long-term follow-up. Furthermore, studies to date have been case reports without a control group to allow comparison of treatment options. Martin et al<sup>24</sup> retrospectively reviewed the results of nonoperative treatment (physical

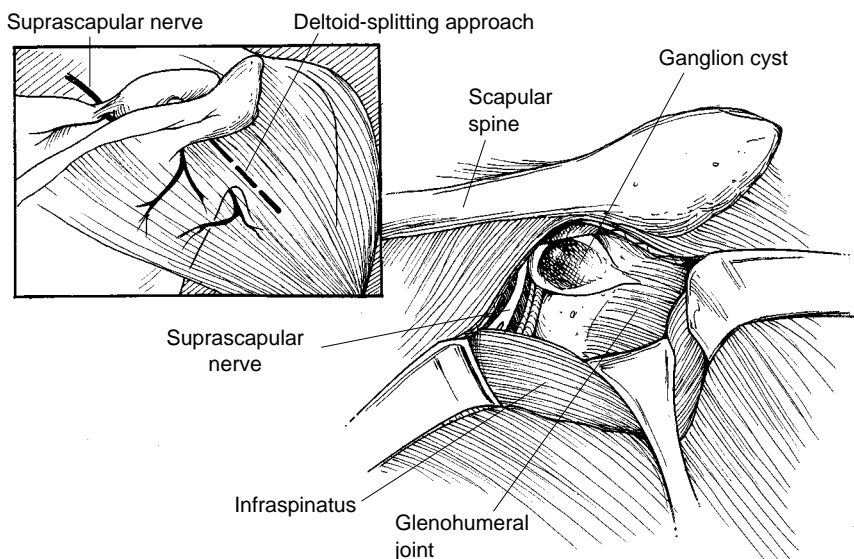


Fig. 7 Posterior approach to the suprascapular nerve at the spinoglenoid notch.

therapy) in 15 patients with suprascapular neuropathy. The average duration of follow-up was more than 3 years. Five patients had excellent results, and seven patients had good results. On the basis of this experience, the authors recommended nonoperative treatment in the absence of a well-defined lesion producing mechanical compression of the suprascapular nerve for patients with a confirmed diagnosis of suprascapular neuropathy.

Callahan et al<sup>32</sup> reported the data on a series of 23 patients with suprascapular neuropathy who were treated with resection of the transverse scapular ligament by means of an open superior approach. Of the 23 patients, 21 (91%) were pain-free immediately after surgery. Seventeen patients remained pain-free, but 3 required reoperation 2 to 4 years after the initial procedure. Overall, 20 of the 23 patients (87%) had long-term relief of pain and resolution of weakness.

Vastamäki and Göransson<sup>33</sup> reported the data on 54 patients with suprascapular neuropathy treated with resection of the suprascapular ligament. The diagnosis was based on the findings from the history, physical examination, and electrodiagnostic studies. The pain disappeared promptly after the procedure in 24 cases (44%), and the decrease in pain was notable in an additional 15 cases (28%). Initially, atrophy had been present in 16 supraspinatus muscles and 26

infraspinatus muscles. At follow-up, atrophy of the supraspinatus muscle was found in only 1 patient, but atrophy of the infraspinatus persisted in 11 patients.

Post and Grinblat<sup>25</sup> reported on 28 patients with suprascapular neuropathy. Open surgical decompression without evaluation or treatment of pathologic changes in the glenoid labrum resulted in excellent or good results in 25 patients (89%).

Fehrman et al<sup>23</sup> reported six cases of suprascapular nerve entrapment due to a ganglion cyst. After failure of nonoperative treatment, all patients had complete pain relief as a result of arthroscopic treatment of intra-articular lesions combined with open resection of ganglia. Long-term follow-up was not available.

Recently, Hawkins et al<sup>20</sup> reported a retrospective analysis of the clinical evaluation and treatment of 73 patients with ganglion cysts in the spinoglenoid notch. Average follow-up was 20.5 months. The greatest satisfaction was reported by the 25 patients who were treated with arthroscopic management of labral lesions and cyst decompression.

### **Summary**

Suprascapular neuropathy should be considered in the differential diagnosis of shoulder pain, especially when other common causes of

shoulder pain have been excluded. Clinical examination of the shoulder should include direct inspection of the shoulder musculature and strength testing of selected muscle groups. Magnetic resonance imaging provides essential information regarding potential causes of suprascapular nerve compression. Electrodiagnostic studies can confirm the diagnosis and can usually localize the site of pathologic changes.

Suprascapular neuropathy without evidence of a compressive lesion generally resolves with nonoperative treatment, although maximum improvement may take more than a year to occur. Symptomatic suprascapular neuropathy related to the site of the suprascapular notch is effectively treated with open surgical decompression by releasing the transverse scapular ligament. Suprascapular neuropathy caused by extrinsic compression from a ganglion cyst should be treated with surgical decompression. Open decompression of the cyst is associated with good to excellent results in most patients. However, MR imaging and arthroscopy have shown a high association of superior-posterior labral tears with ganglion cysts of the shoulder. Therefore, treatment of the labral disorder and decompression of the cyst is recommended to achieve the best outcome. Arthroscopic decompression of the cyst is technically challenging but possible, and may provide a more rapid recovery.

## References

- Kopell HP, Thompson WAL: Pain and the frozen shoulder. *Surg Gynecol Obstet* 1959;109:92-96.
- Aiello I, Serra G, Traina GC, Tugnoli V: Entrapment of the suprascapular nerve at the spinoglenoid notch. *Ann Neurol* 1982;12:314-316.
- Herzog RJ: Magnetic resonance imaging of the shoulder. *J Bone Joint Surg Am* 1997;79:934-953.
- Mallon WJ, Bronc PR, Spinner RJ, Levin LS: Suprascapular neuropathy after distal clavicle excision. *Clin Orthop* 1996;329:207-211.
- Post M, Mayer J: Suprascapular nerve entrapment: Diagnosis and treatment. *Clin Orthop* 1987;223:126-136.
- Edelson JG: Bony bridges and other variations of the suprascapular notch. *J Bone Joint Surg Br* 1994;77:505-506.
- Rengachary SS, Burr D, Lucas S, Hassanein KM, Mohn MP, Matzke H: Suprascapular entrapment neuropathy: A clinical, anatomical, and comparative study—Part 2. Anatomical study. *Neurosurgery* 1979;5:447-451.
- Ticker JB, Djurasovic M, Strauch RJ, et al: The incidence of ganglion cysts and other variations in anatomy along the course of the suprascapular nerve. *J Shoulder Elbow Surg* 1998;7:472-478.
- Warner JJP, Krushell RJ, Masquelet A, Gerber C: Anatomy and relationships of the suprascapular nerve: Anatomical constraints to mobilization of the supraspinatus and infraspinatus muscles in the management of massive rotator-cuff tears. *J Bone Joint Surg Am* 1992;74:36-45.
- Bigliani LU, Dalsey RM, McCann PD, April EW: An anatomical study of the suprascapular nerve. *Arthroscopy* 1990;6:301-305.
- Demaio M, Drez D Jr, Mullins RC: The inferior transverse scapular ligament as a possible cause of entrapment neuropathy of the nerve to the infraspinatus: A brief note. *J Bone Joint Surg Am* 1991;73:1061-1063.
- Demirhan M, Imhoff AB, Debski RE, Patel PR, Fu FH, Woo SLY: The spinoglenoid ligament and its relationship to the suprascapular nerve. *J Shoulder Elbow Surg* 1998;7:238-243.
- Cummins CA, Anderson K, Bowen M, Nuber G, Roth SI: Anatomy and histological characteristics of the spinoglenoid ligament. *J Bone Joint Surg Am* 1998;80:1622-1625.
- Ringel SP, Treihhaft M, Carry M, Fisher R, Jacobs P: Suprascapular neuropathy in pitchers. *Am J Sports Med* 1990;18:80-86.
- de Laat EAT, Visser CPJ, Coene LNJEM, Pahlplatz PVM, Tavy DLJ: Nerve lesions in primary shoulder dislocations and humeral neck fractures: A prospective clinical and EMG study. *J Bone Joint Surg Br* 1994;76:381-383.
- Edeland HG, Zachrisson BE: Fracture of the scapular notch associated with lesion of the suprascapular nerve. *Acta Orthop Scand* 1975;46:758-763.
- Shaffer BS, Conway J, Jobe FW, Kvitne RS, Tibone JE: Infraspinatus muscle-splitting incision in posterior shoulder surgery: An anatomic and electromyographic study. *Am J Sports Med* 1994;22:113-120.
- Inokuchi W, Ogawa K, Horiuchi Y: Magnetic resonance imaging of suprascapular nerve palsy. *J Shoulder Elbow Surg* 1998;7:223-227.
- Tirman PFJ, Feller JF, Janzen DL, Peterfy CG, Bergman AG: Association of glenoid labral cysts with labral tears and glenohumeral instability: Radiologic findings and clinical significance. *Radiology* 1994;190:653-658.
- Hawkins RJ, Piatt BE, Fritz RC, Wolf E, Schickendantz M: Clinical evaluation and treatment of spinoglenoid notch ganglion cysts [abstract]. *J Shoulder Elbow Surg* 1999;8:551.
- Moore TP, Fritts HM, Quick DC, Buss DD: Suprascapular nerve entrapment caused by supraglenoid cyst compression. *J Shoulder Elbow Surg* 1997;6:455-462.
- Ferretti A, Cerullo G, Russo G: Suprascapular neuropathy in volleyball players. *J Bone Joint Surg Am* 1987;69:260-263.
- Fehrman DA, Orwin JF, Jennings RM: Suprascapular nerve entrapment by ganglion cysts: A report of six cases with arthroscopic findings and review of the literature. *Arthroscopy* 1995;11:727-734.
- Martin SD, Warren RF, Martin TL, Kennedy K, O'Brien SJ, Wickiewicz TL: Suprascapular neuropathy: Results of non-operative treatment. *J Bone Joint Surg Am* 1997;79:1159-1165.
- Post M, Grinblat E: Suprascapular nerve entrapment: Diagnosis and results of treatment. *J Shoulder Elbow Surg* 1993;2:190-197.
- Goss TP, Aronow MS, Coumas JM: The use of MRI to diagnose suprascapular nerve entrapment caused by a ganglion. *Orthopedics* 1994;17:359-362.
- Moore TP, Hunter RE: Suprascapular nerve entrapment. *Operative Techniques Sports Med* 1996;4:8-14.
- Black KP, Lombardo JA: Suprascapular nerve injuries with isolated paralysis of the infraspinatus. *Am J Sports Med* 1990;18:225-228.
- Neviaser TJ, Ain BR, Neviaser RJ: Suprascapular nerve denervation secondary to attenuation by a ganglionic cyst. *J Bone Joint Surg Am* 1986;68:627-628.
- Fritz RC, Helms CA, Steinbach LS, Genant HK: Suprascapular nerve entrapment: Evaluation with MR imaging. *Radiology* 1992;182:437-444.
- Iannotti JP, Ramsey ML: Arthroscopic decompression of a ganglion cyst causing suprascapular nerve compression. *Arthroscopy* 1996;12:739-745.
- Callahan JD, Scully TB, Shapiro SA, Worth RM: Suprascapular nerve entrapment: A series of 27 cases. *J Neurosurg* 1991;74:893-896.
- Vastamäki M, Göransson H: Suprascapular nerve entrapment. *Clin Orthop* 1993;297:135-143.